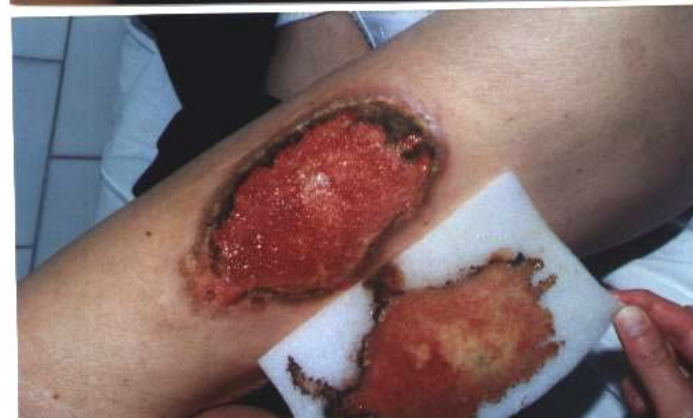
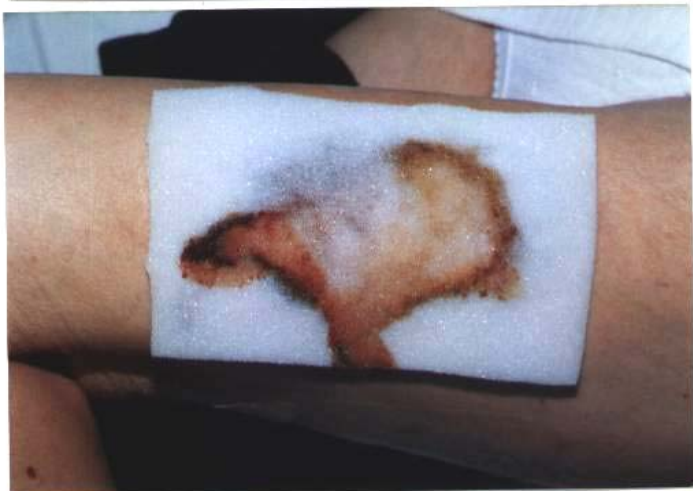
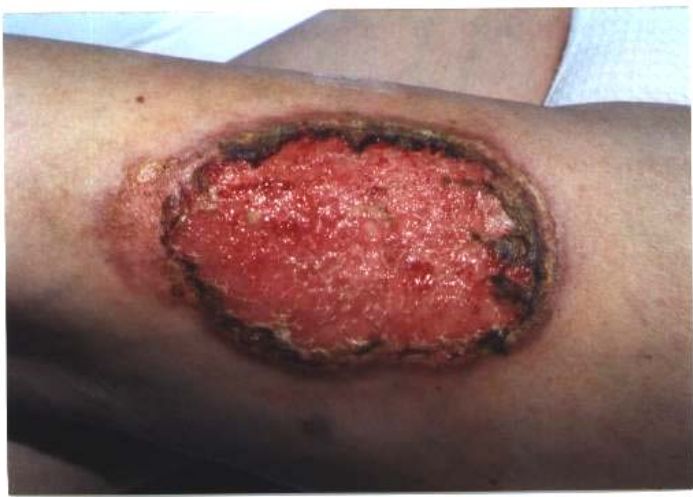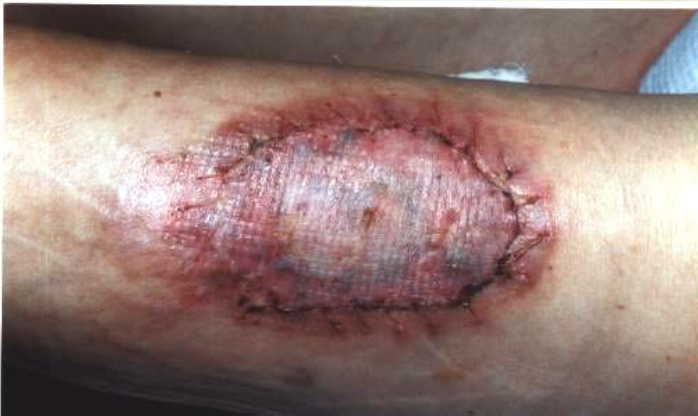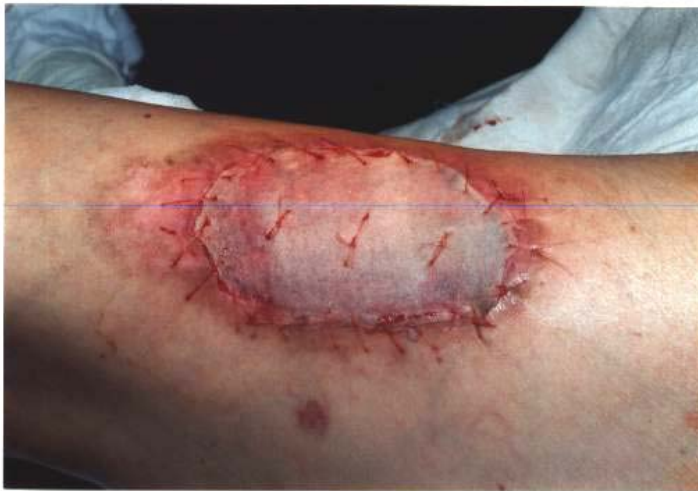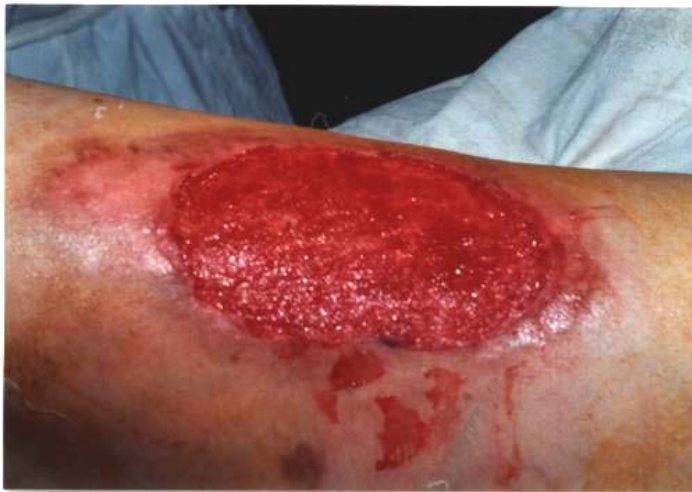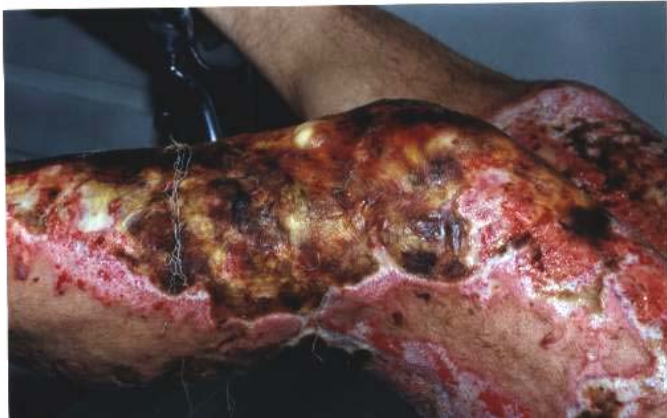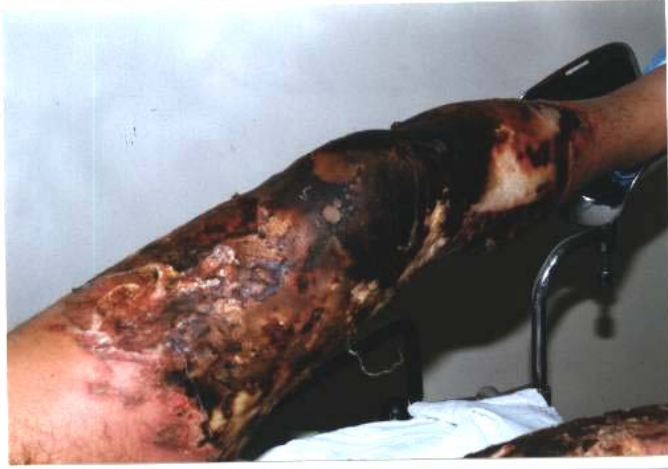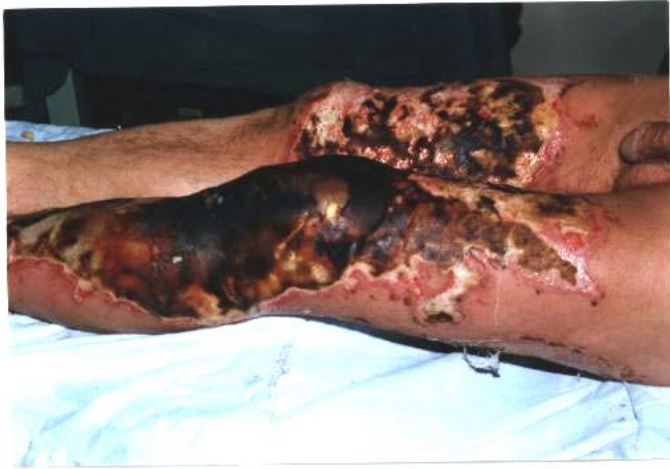# LIGASANO FOAM DRESSING AND ITS MULTIPLE USES IN PLASTIC SURGERY

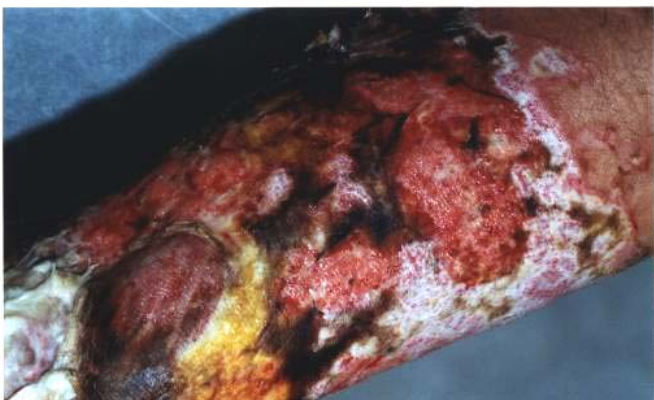
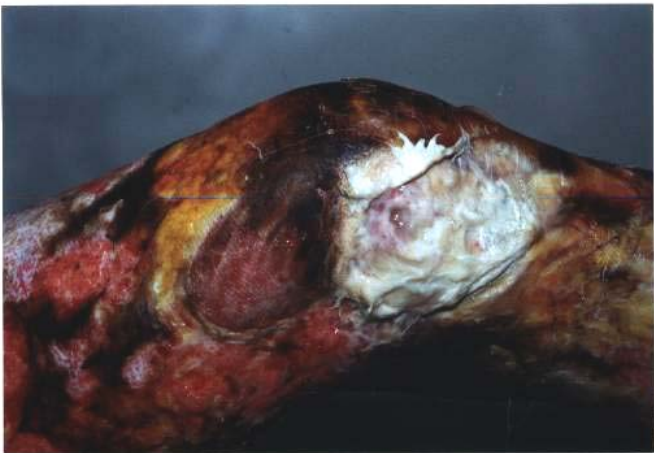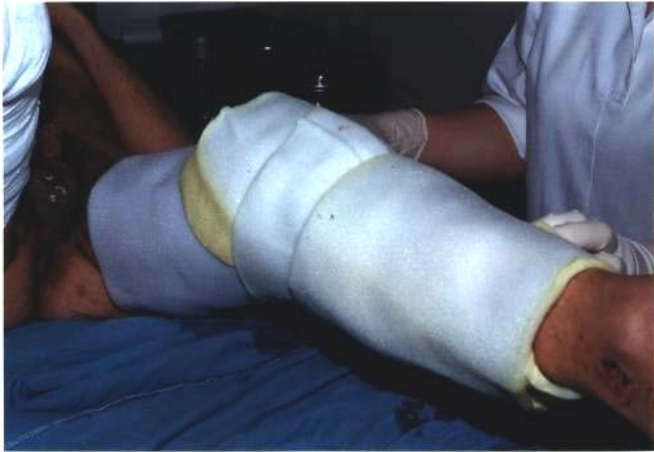- CASE 1. P.J.65 YEAR – FEMALE FULL THICKNESS CONTACT BURN
- 6 PHOTOS

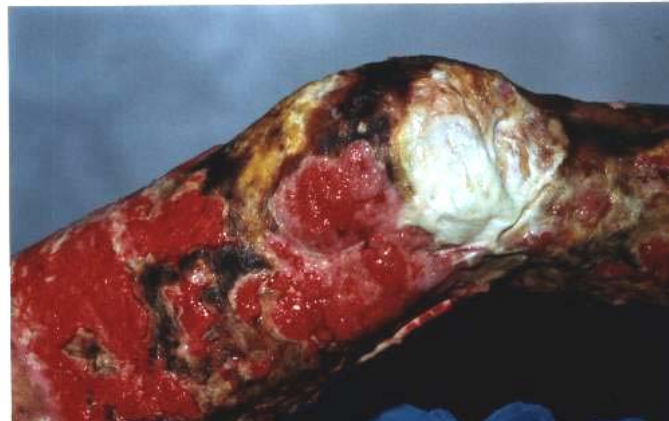
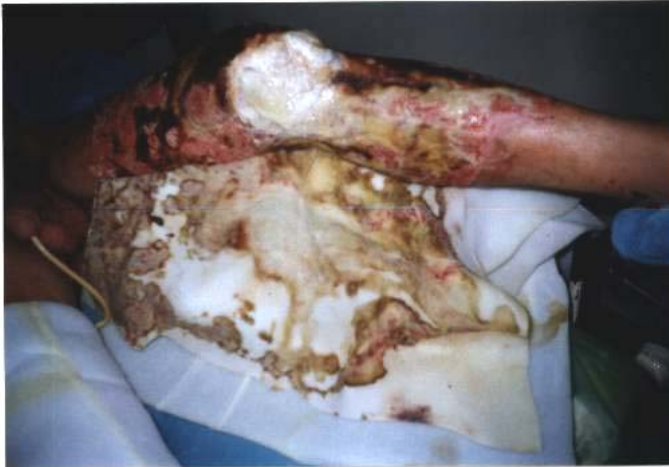
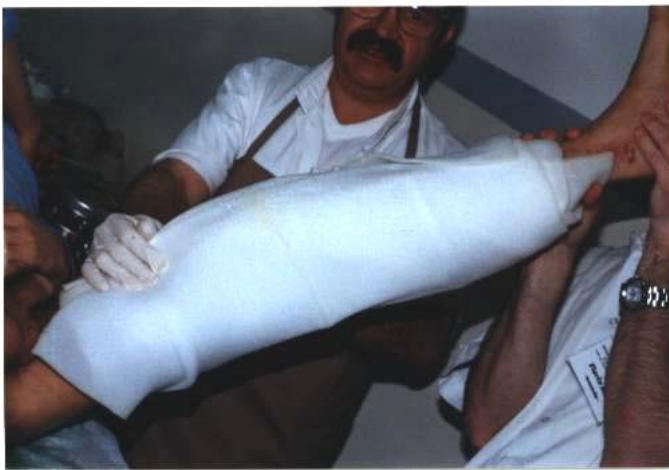

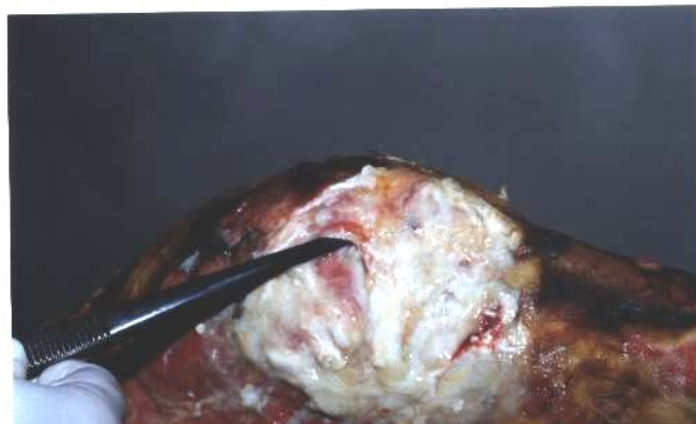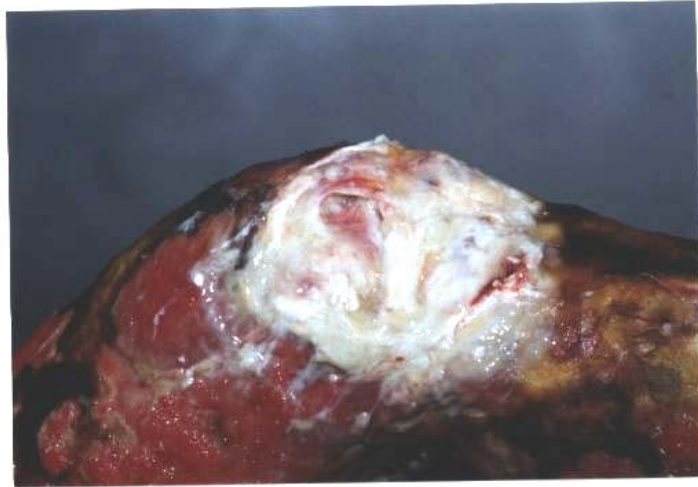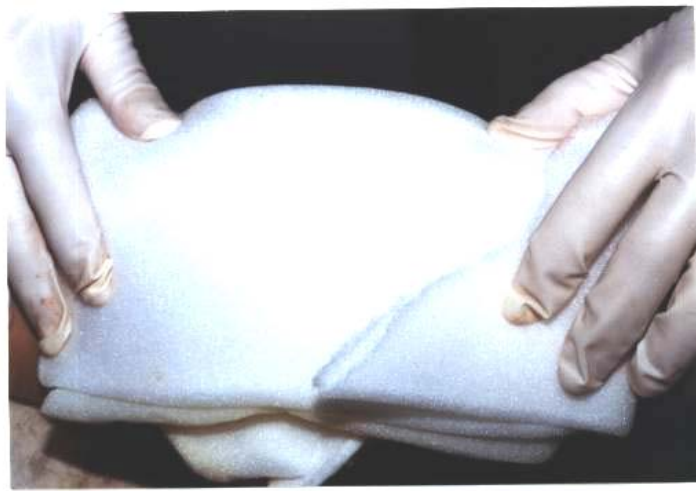- CASE 2. K.L. 50 YEAR MALE
- FULL THICKNESS FLAME BURN
- 23 PHOTOS

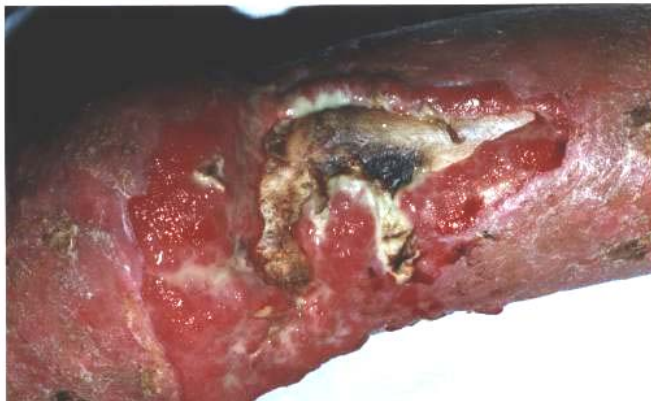
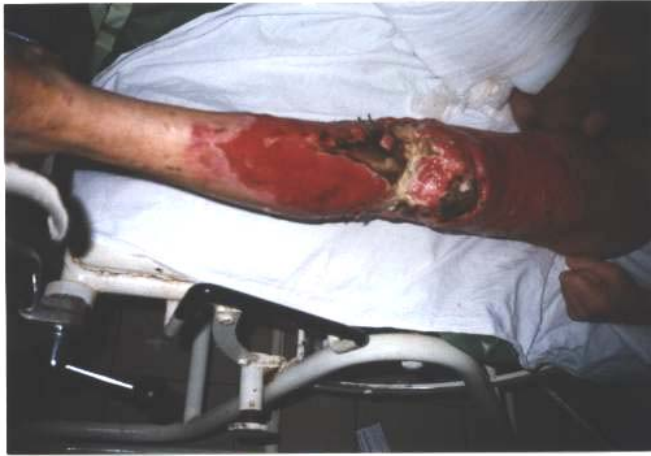
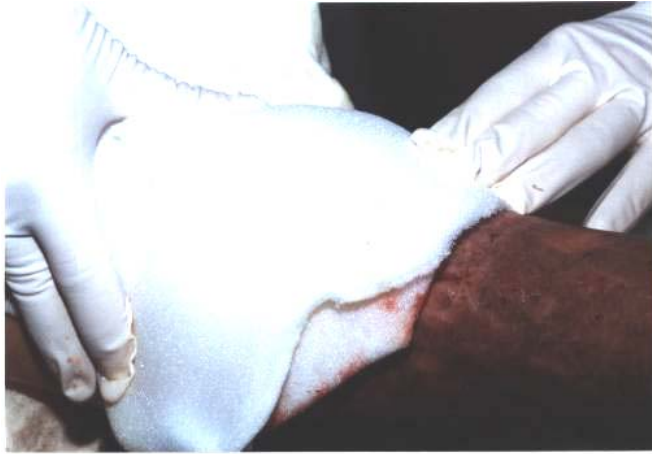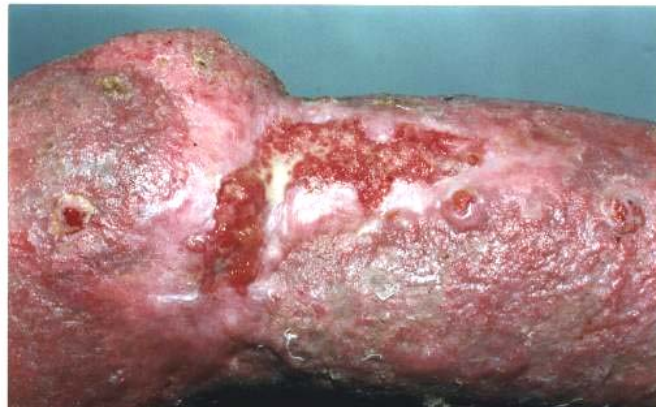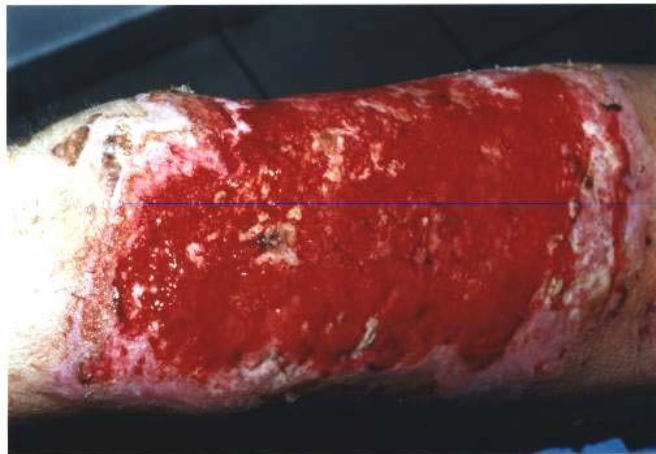
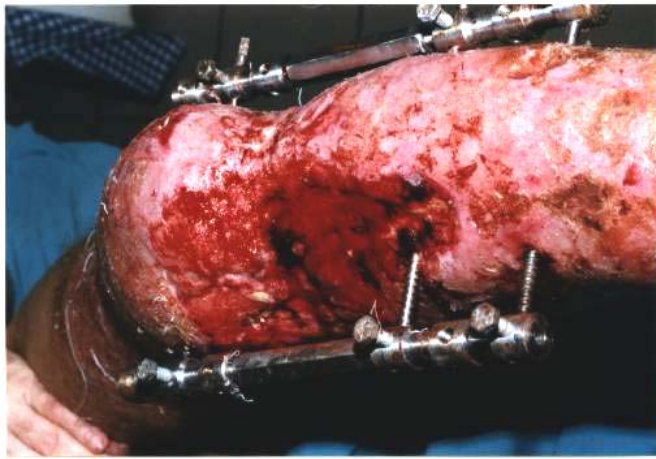






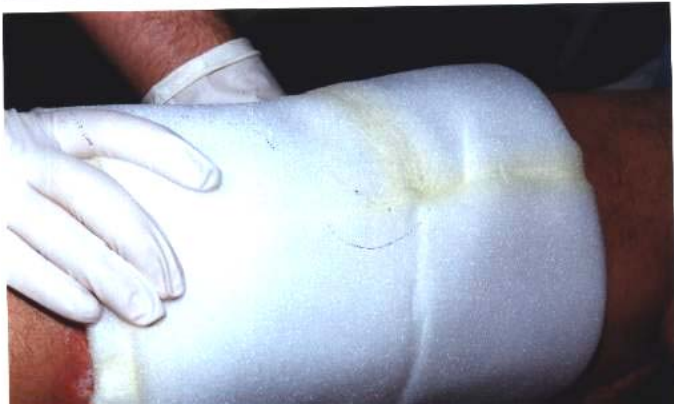
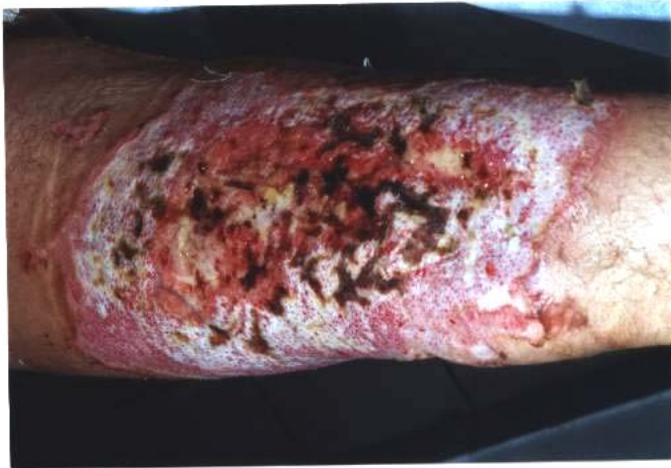
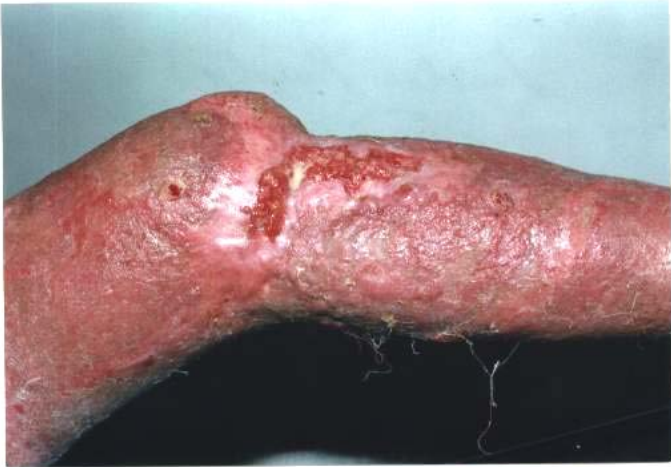


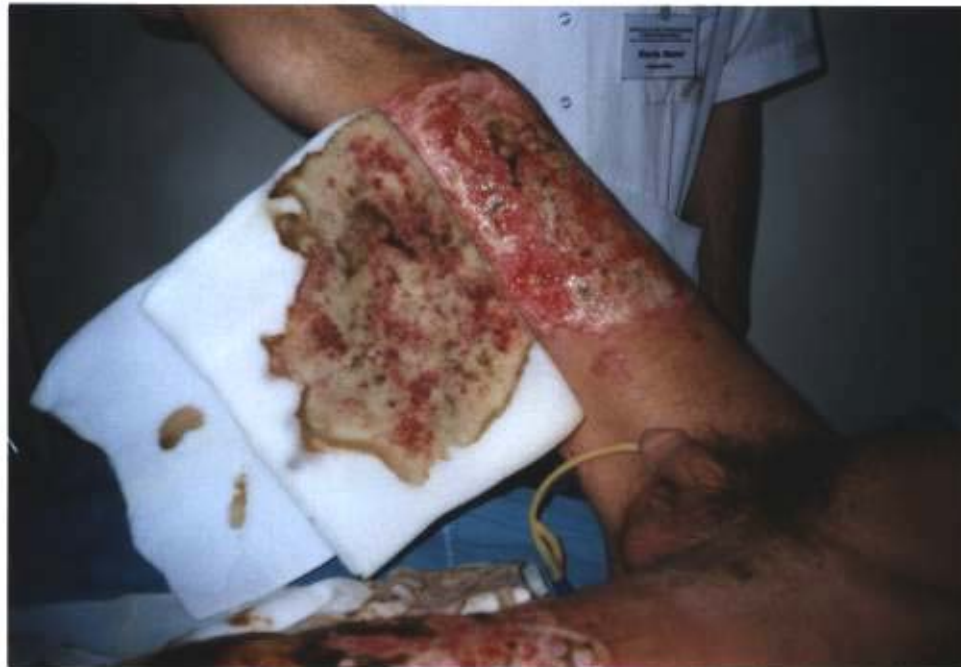
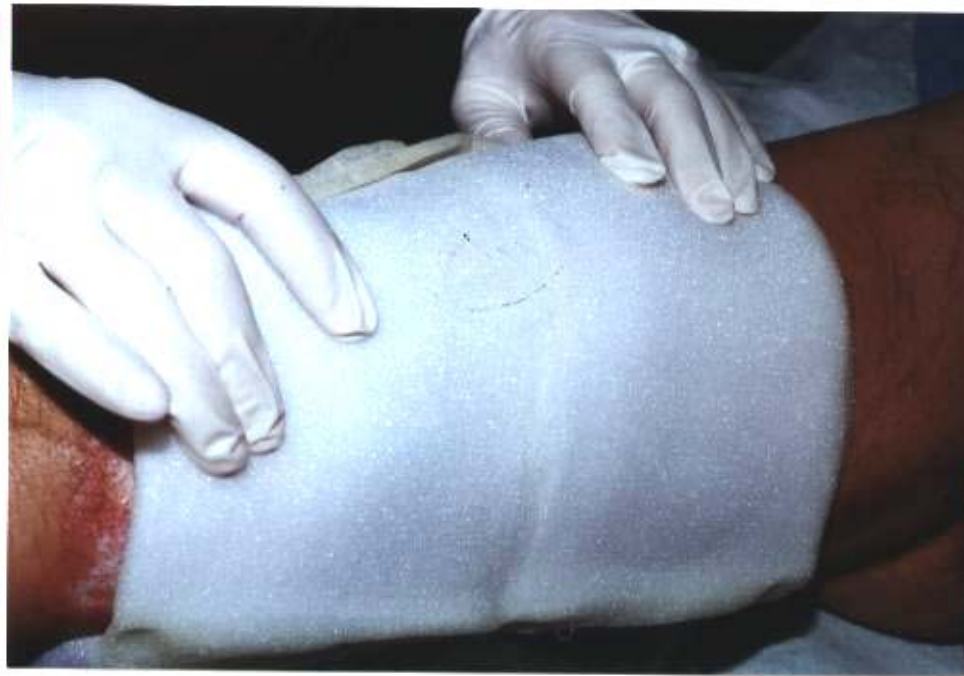



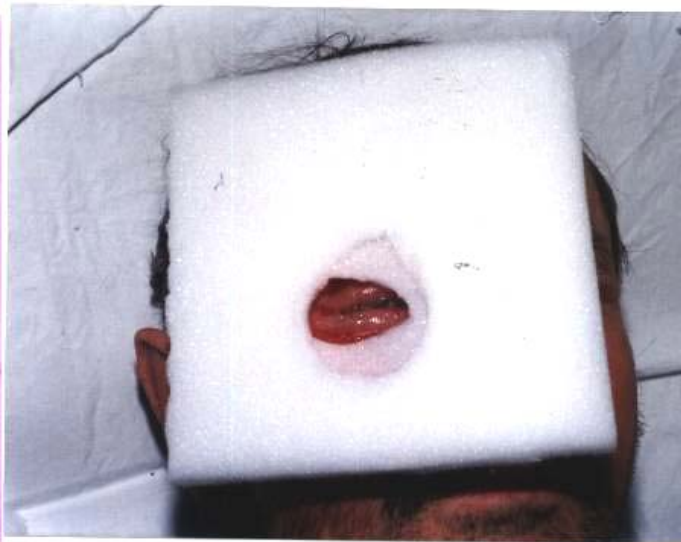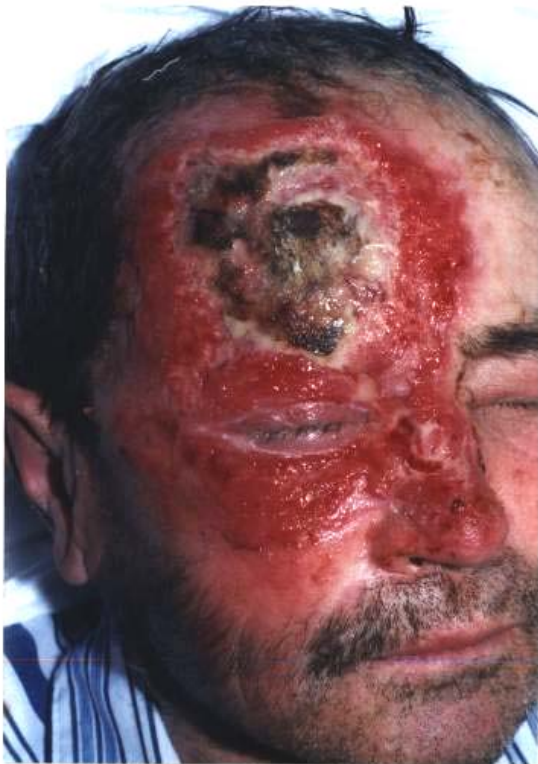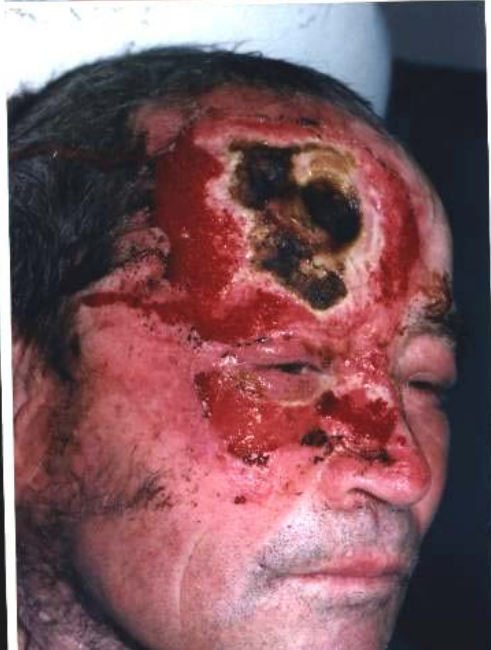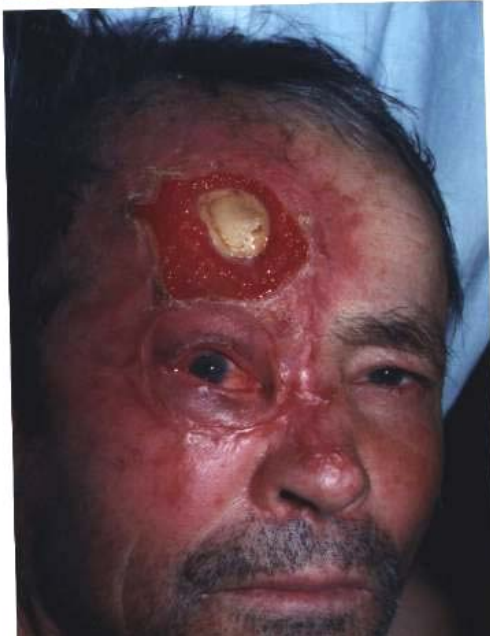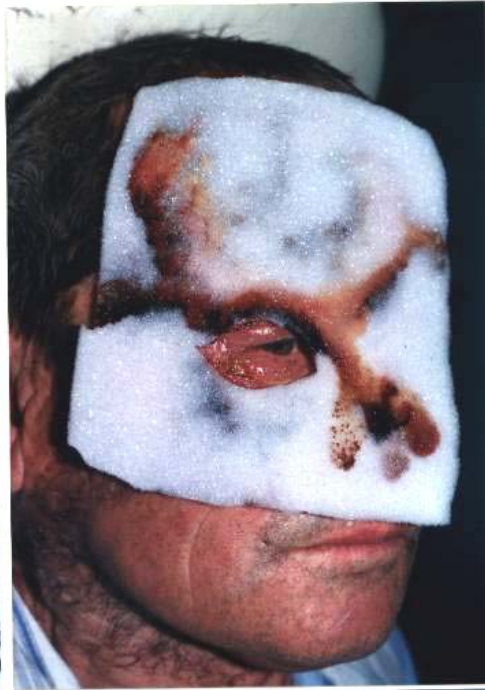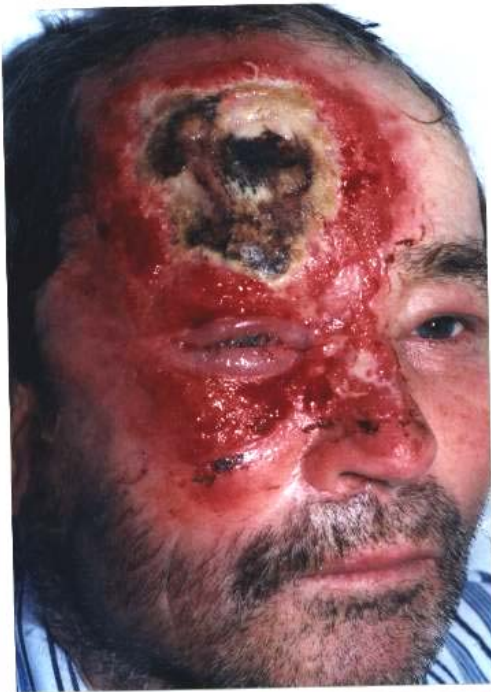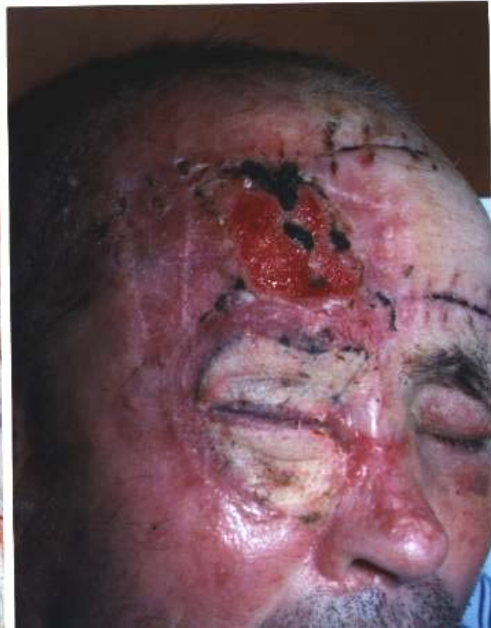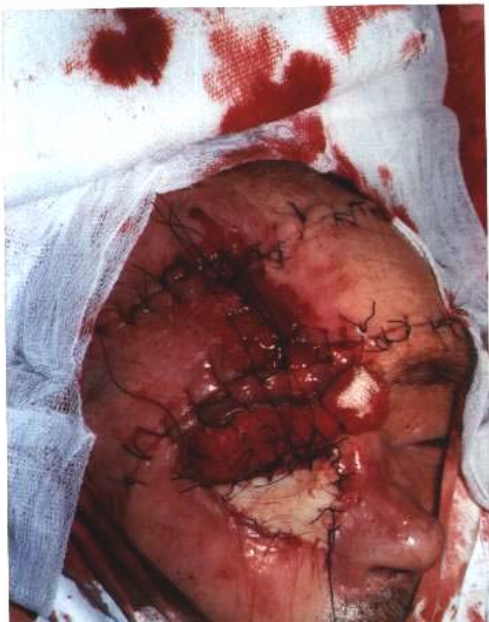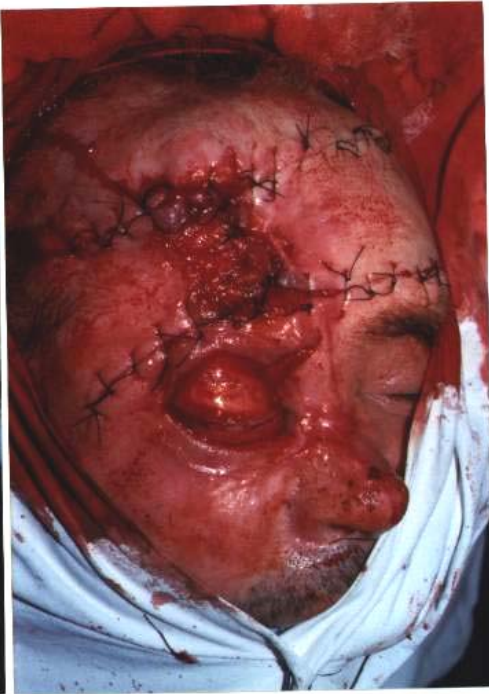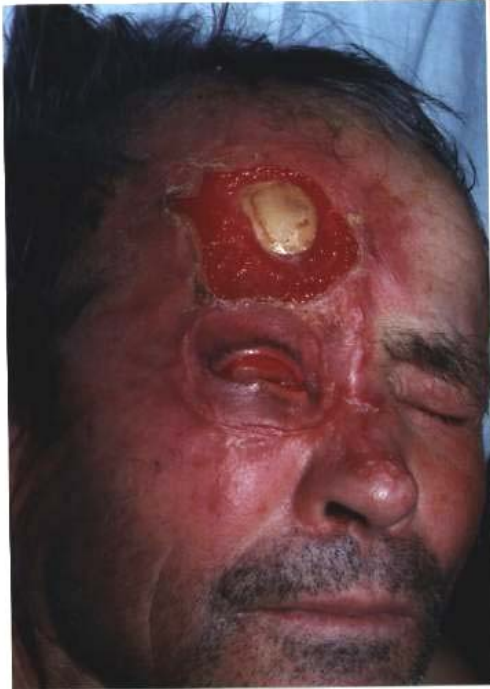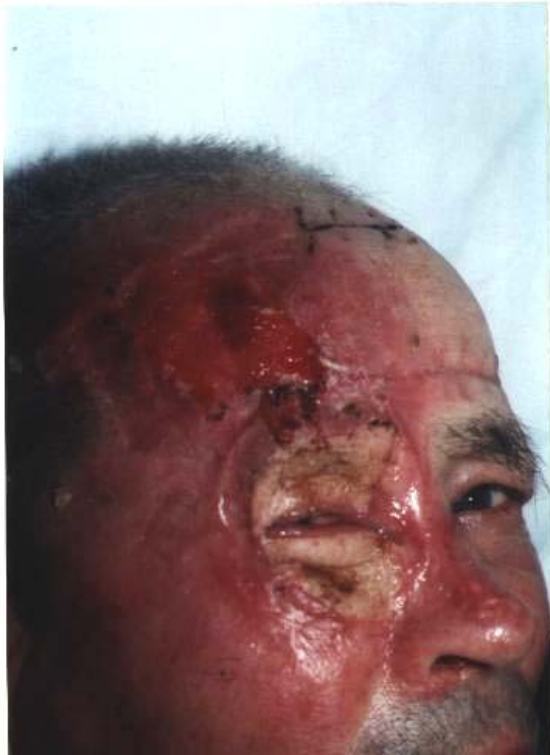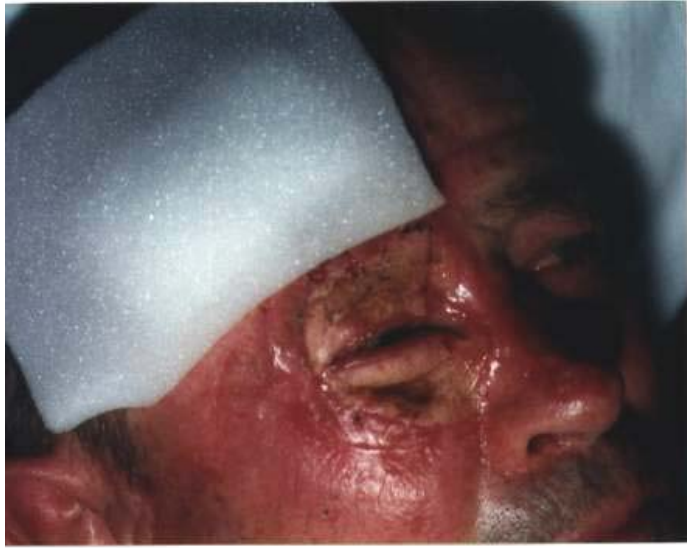- CASE 3. O.G. 75 YEAR MALE
- FULL THICKNESS FACIAL BURN
- 15 PHOTOS

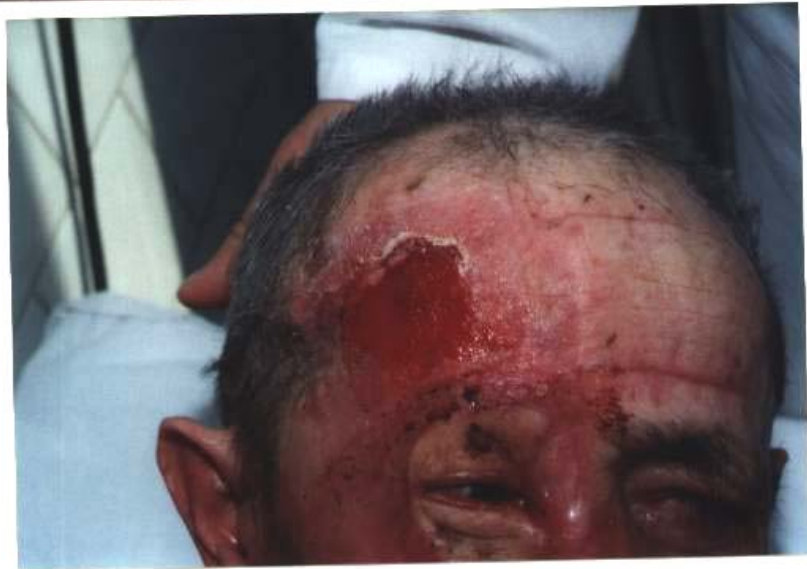
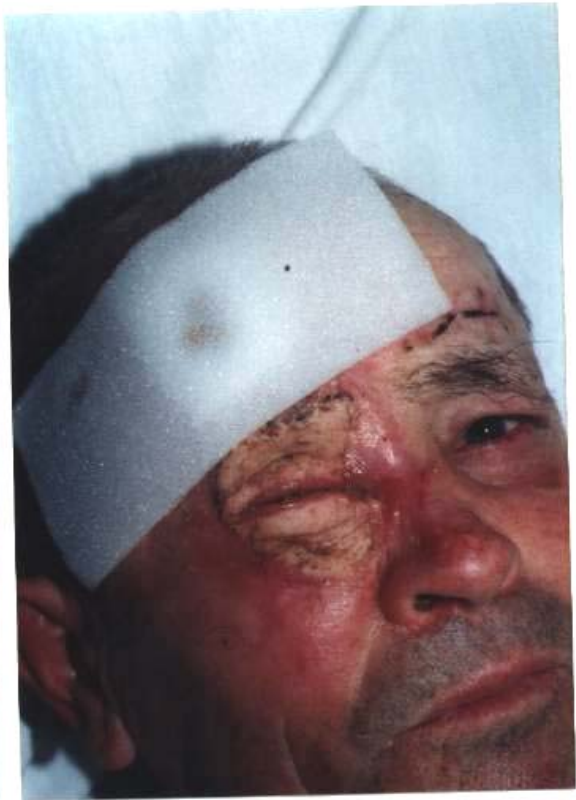
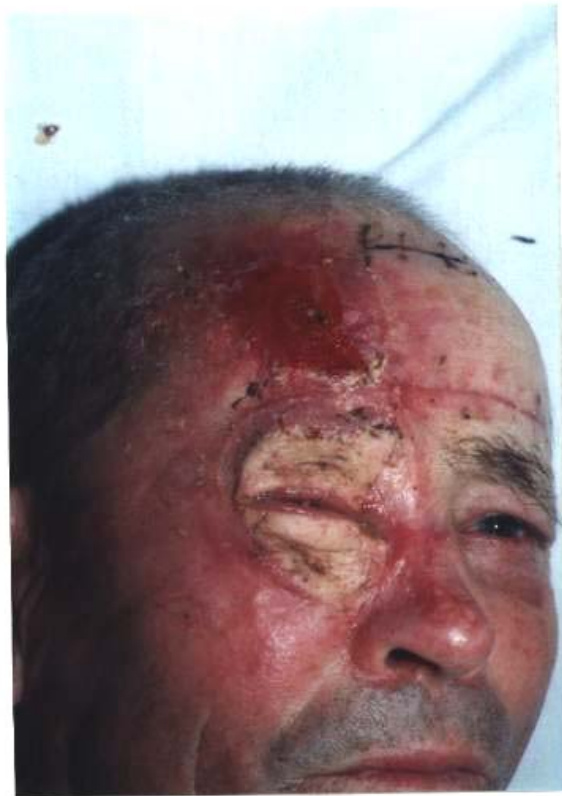




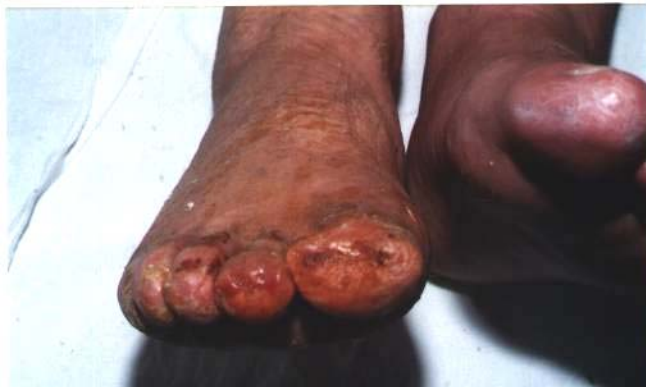
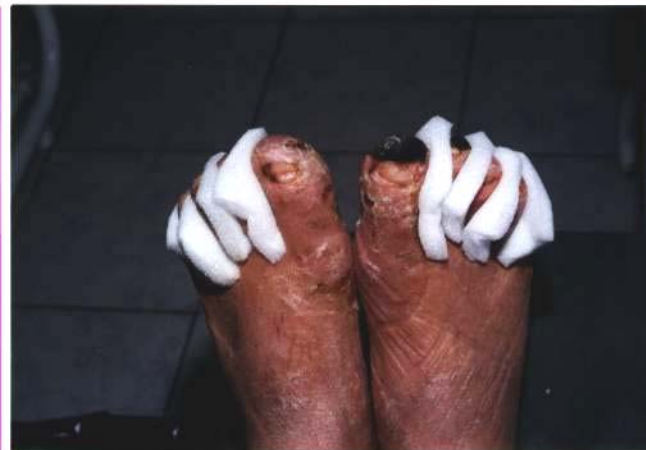
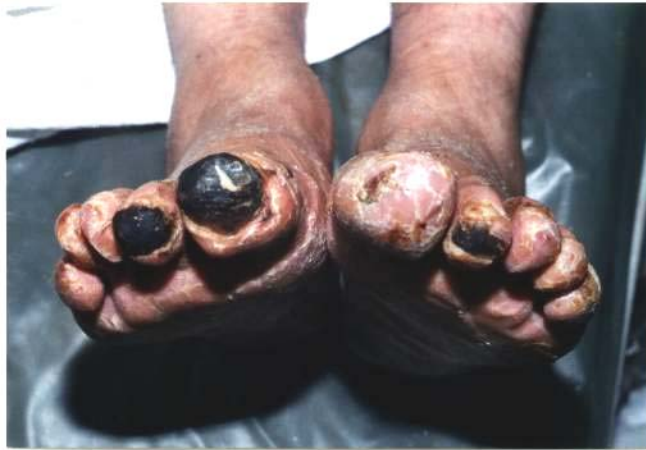


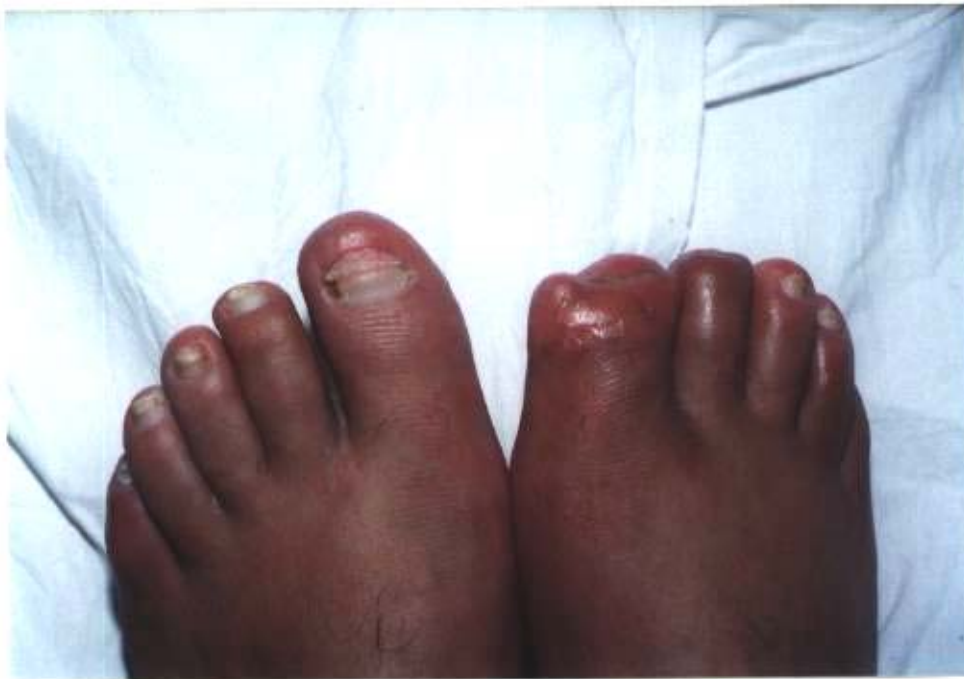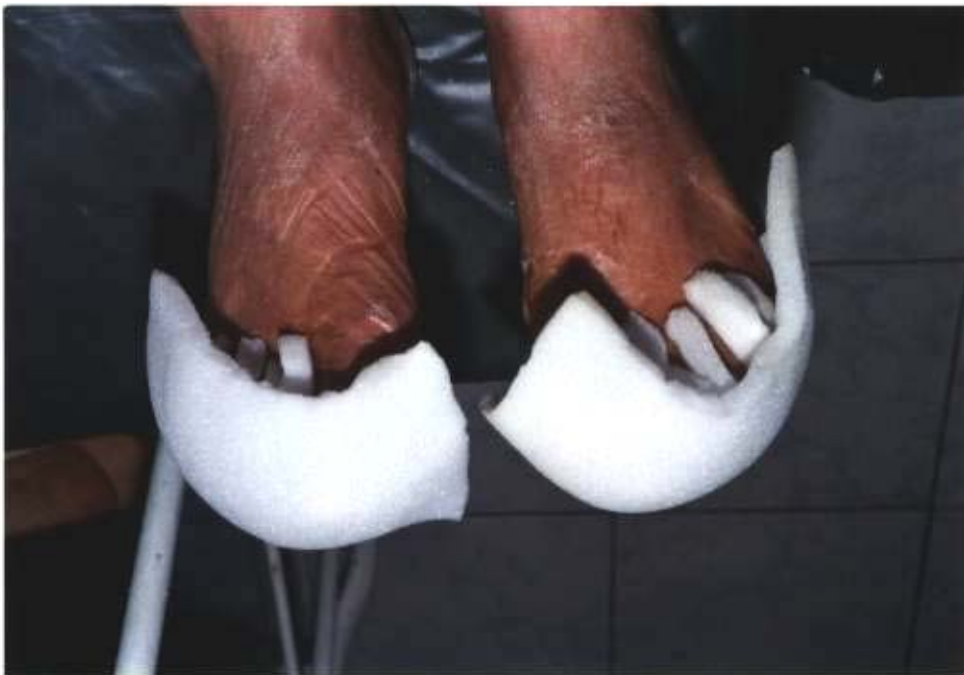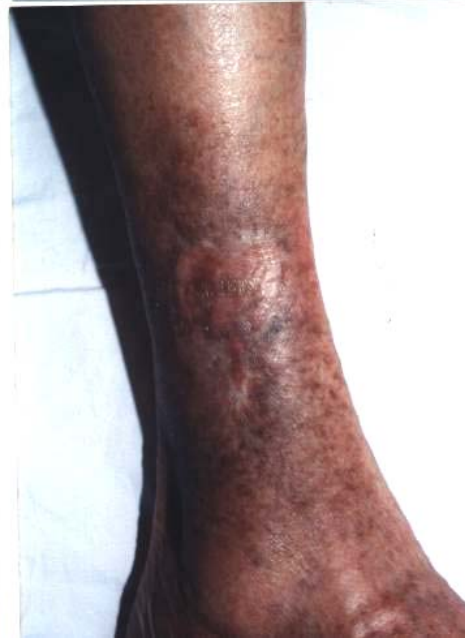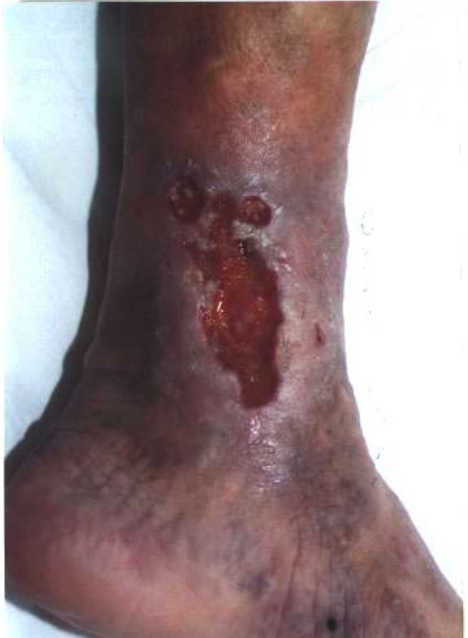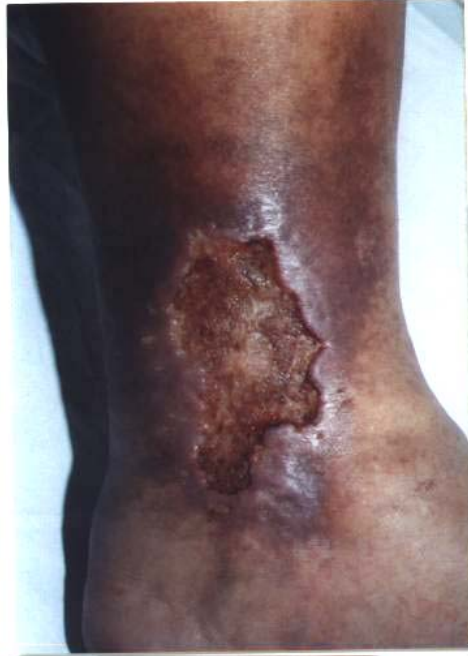- CASE 4.K.A. 38 YEAR MALE
- THIRD DEGREE FROSTBITE
- 5 PHOTOS



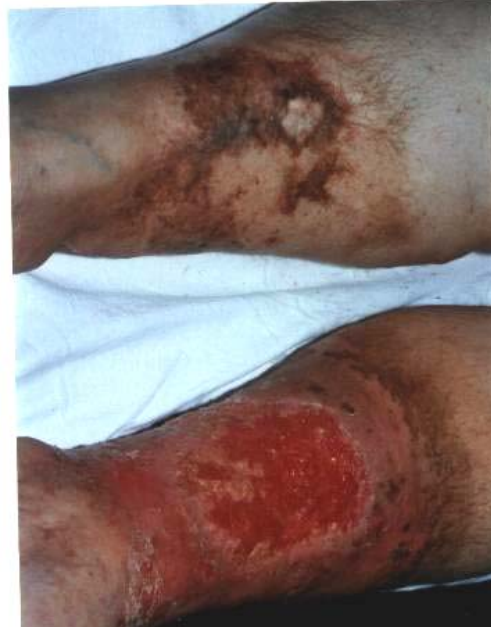
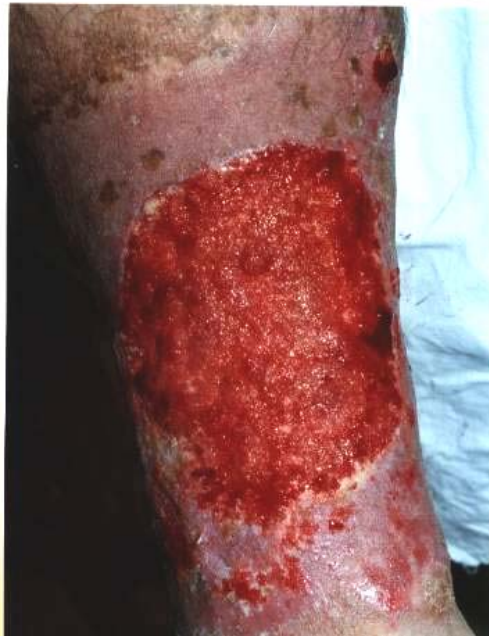
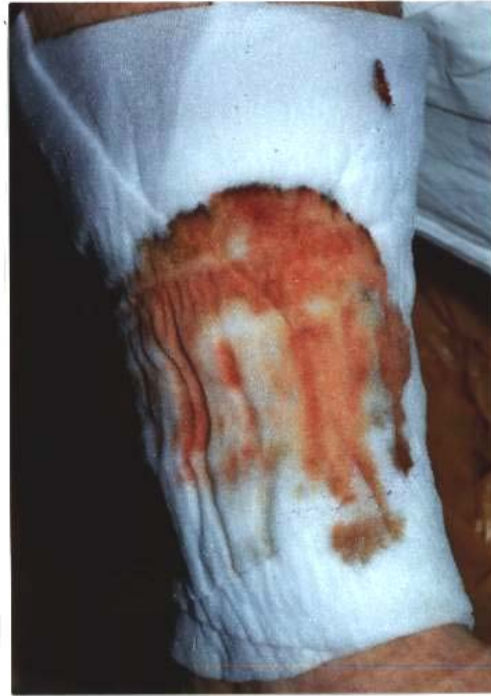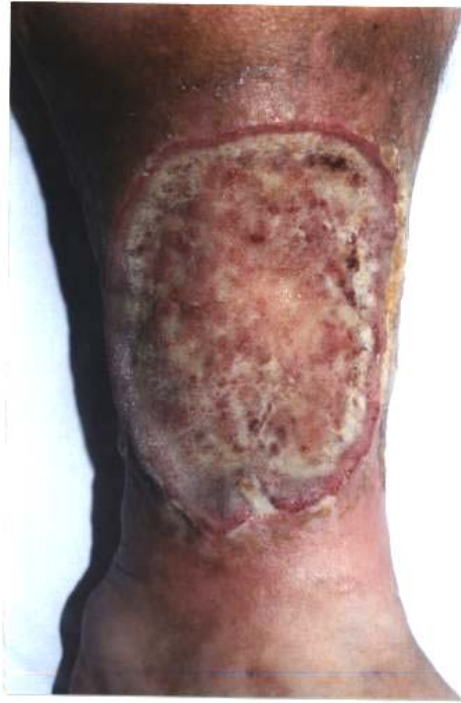- CASE 5.M.E. 57 YEAR FEMALE
- VERY OLD NEGLECTED VENOUS LEG  
ULCER
- 4 PHOTOS

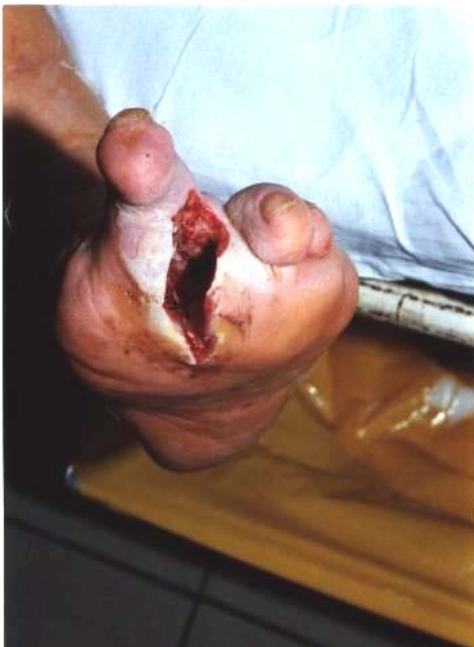
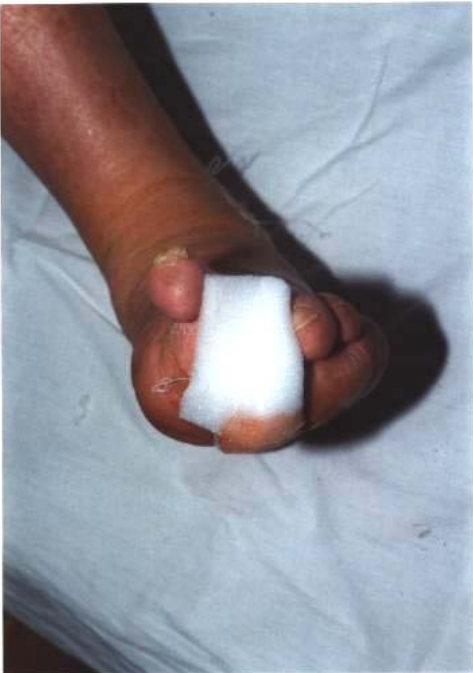


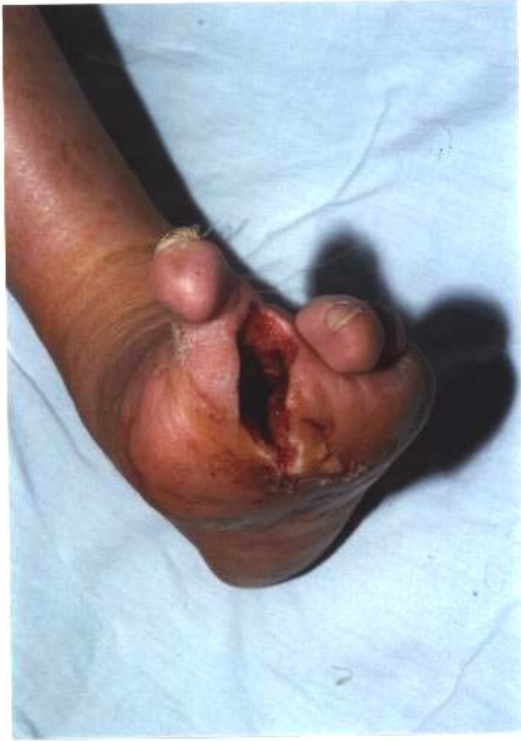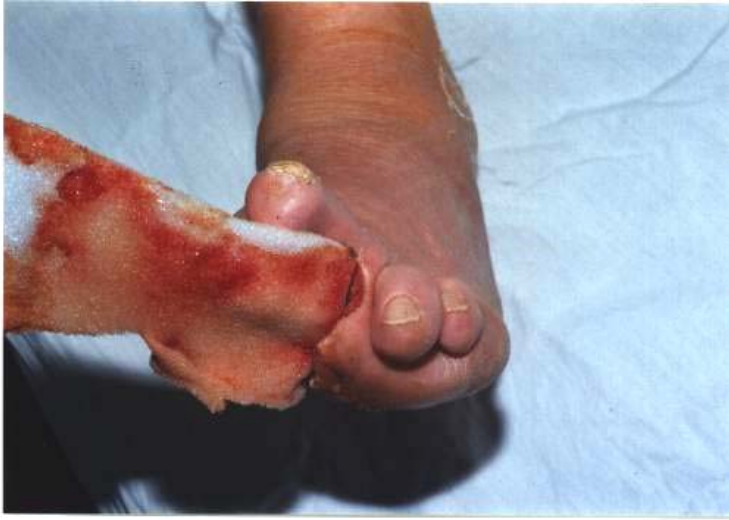- CASE 6. P.I. 45 YEAR MALE
- OLD VENOUS ULCER OF THE LEFT LEG
- 4 PHOTOS

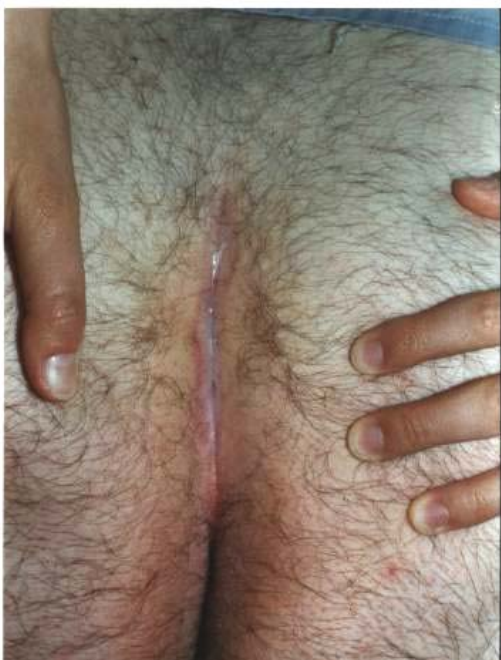
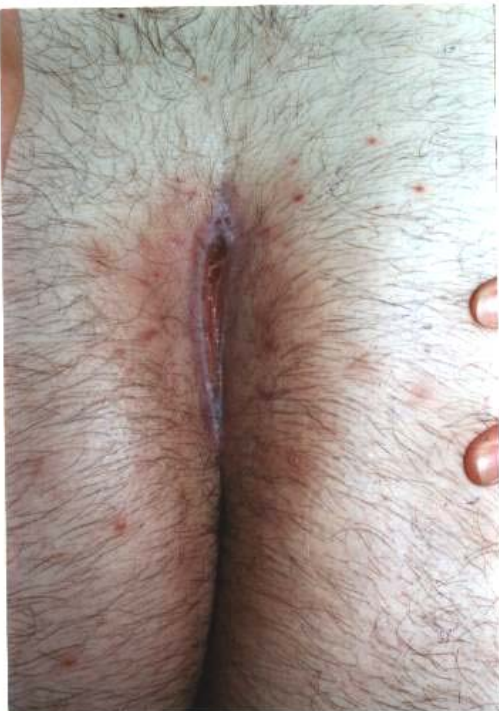
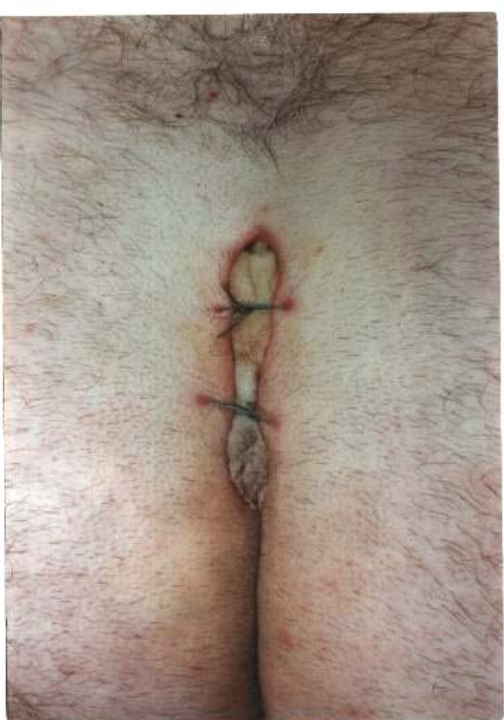- CASE 7. K. E. 61 YEAR MALE
- DIABETIC FOOT (CHARCOT FOOT)
- 4 PHOTOS



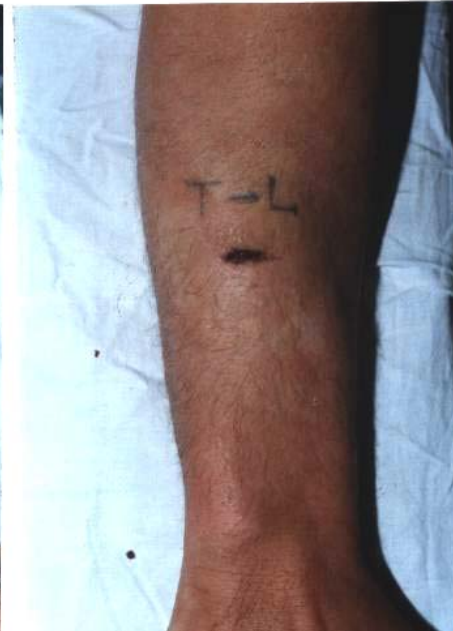
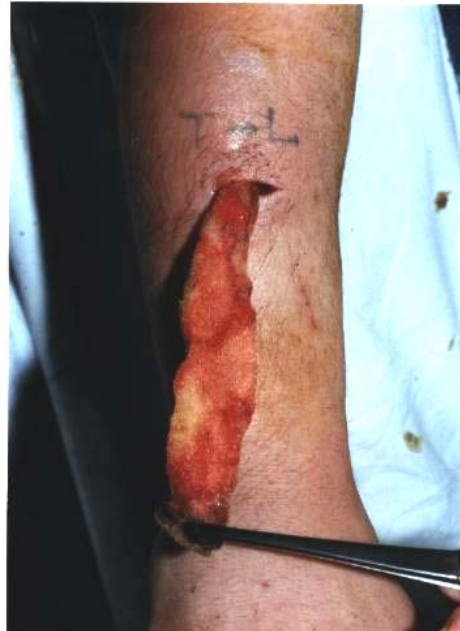
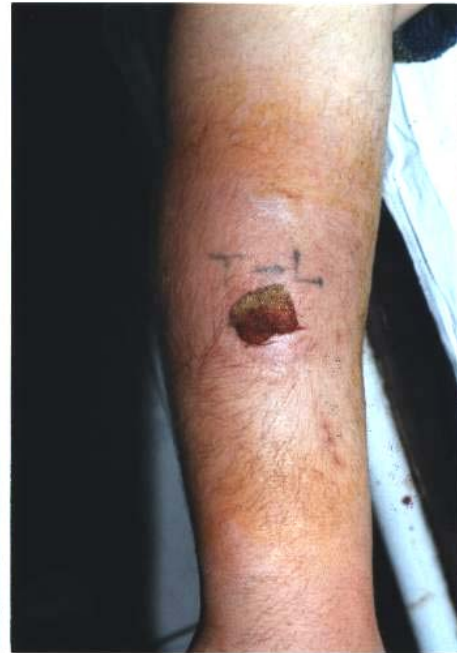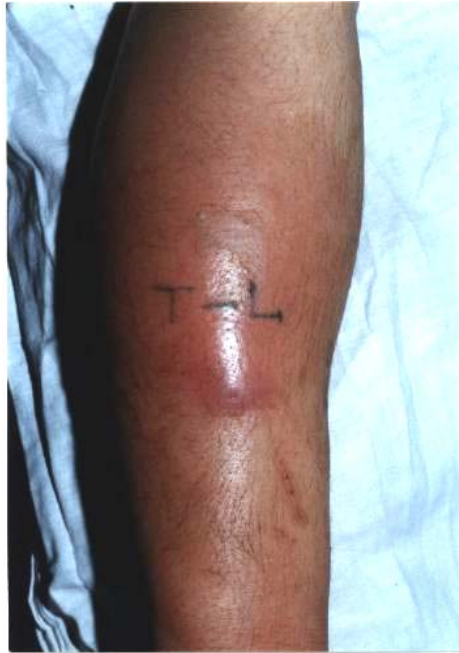- CASE 8. B.D. 33 YEAR MALE
- PILONIDAL SINUS
- 3 PHOTOS

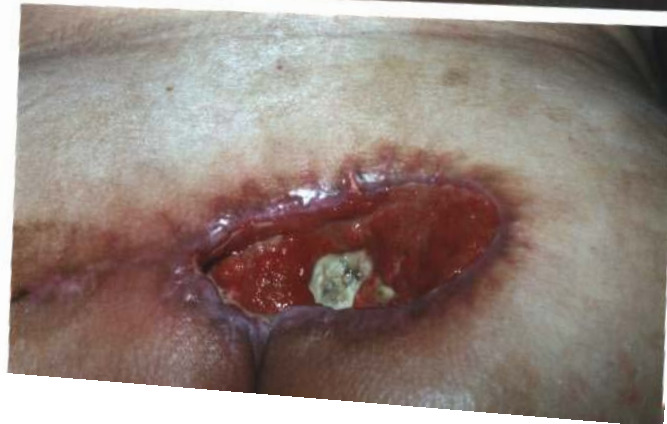
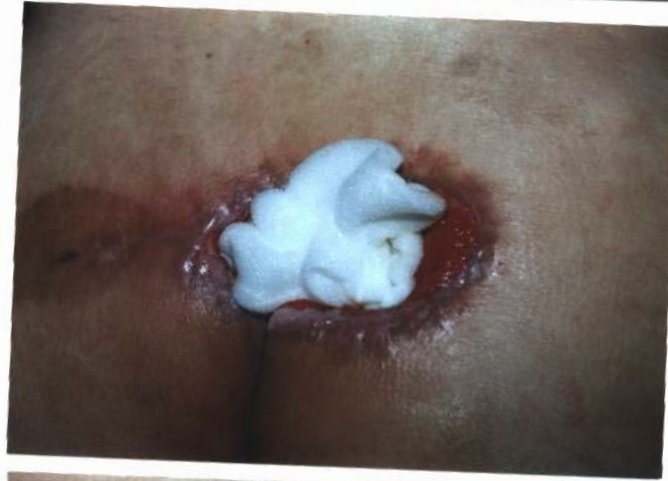
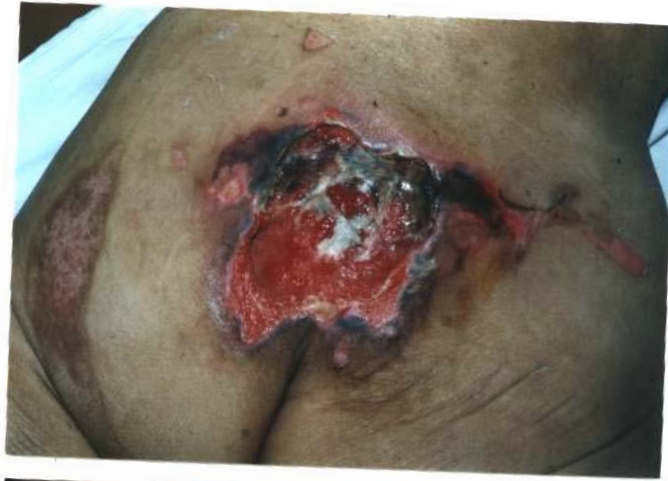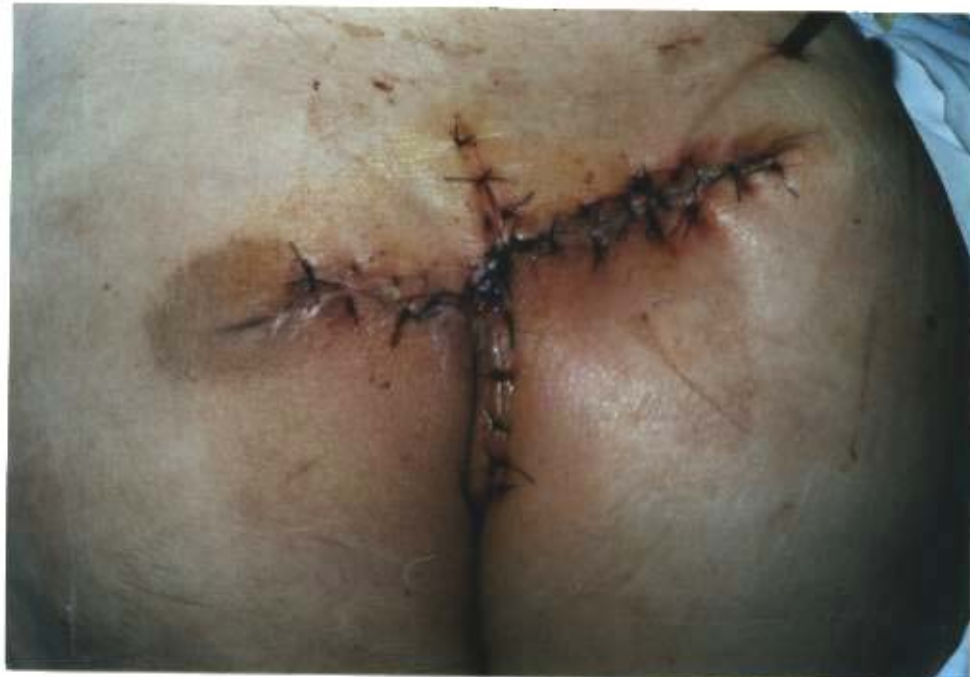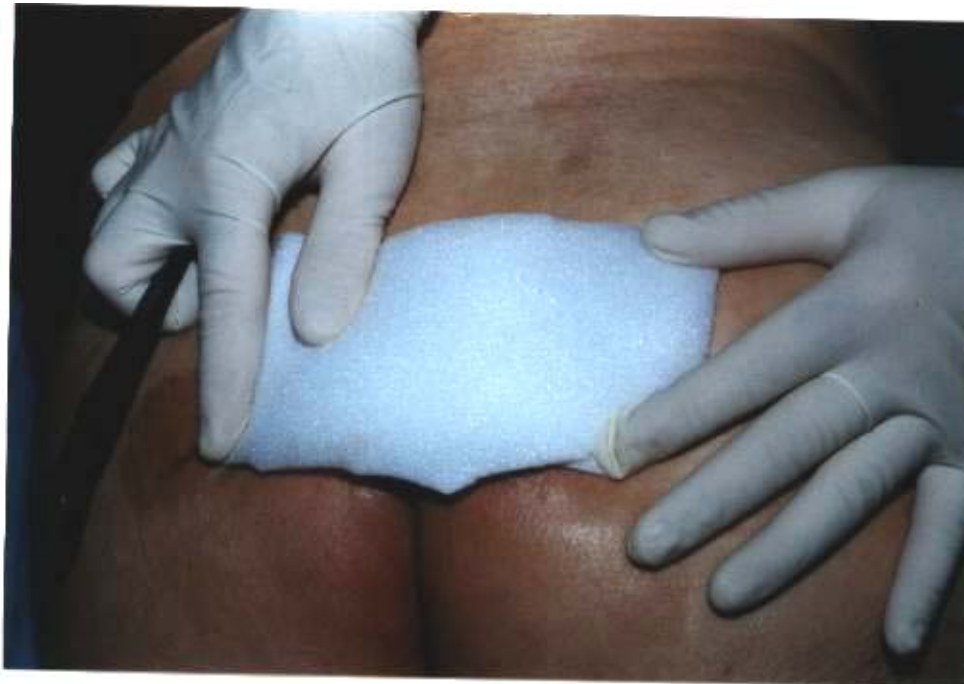- CASE 9. T.G. 29 YEAR MALE
- LEFT FORE – ARM ABSCESS DRAINED  
VITH LIGASANO
- 4 PHOTOS



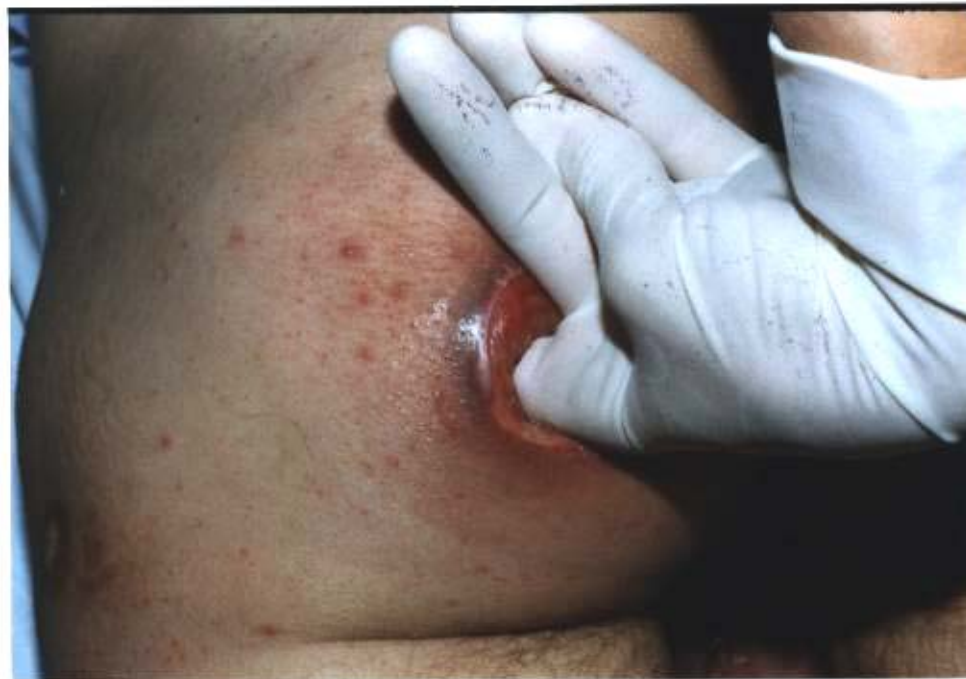
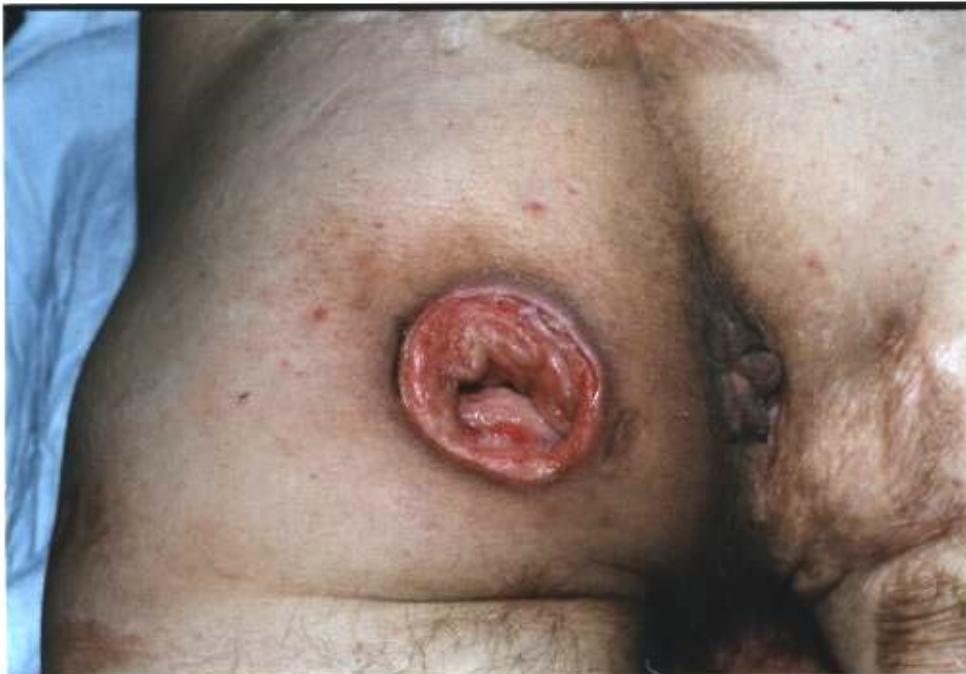
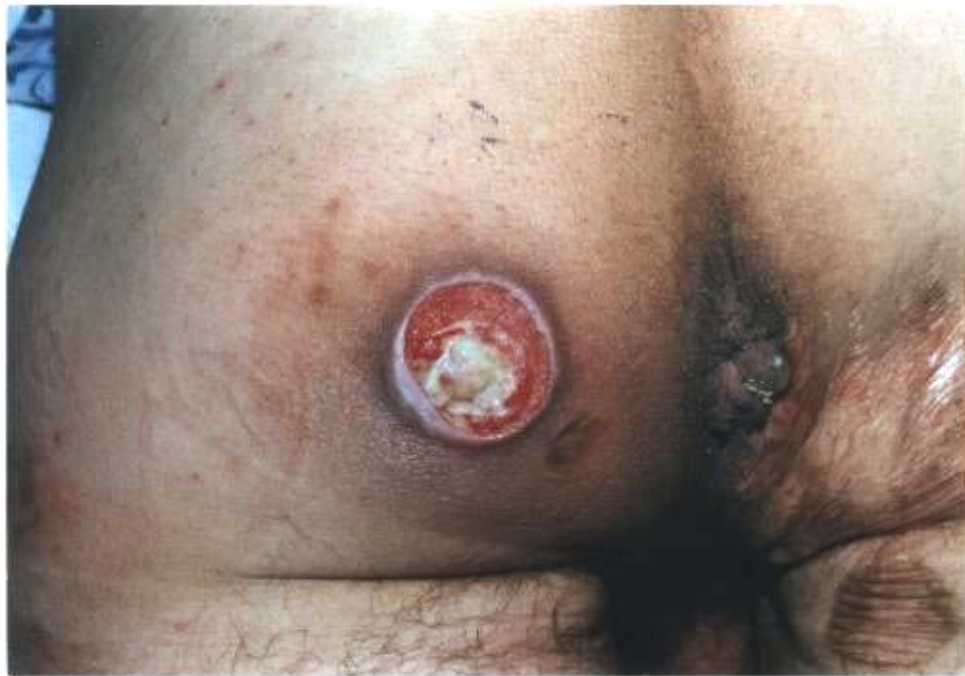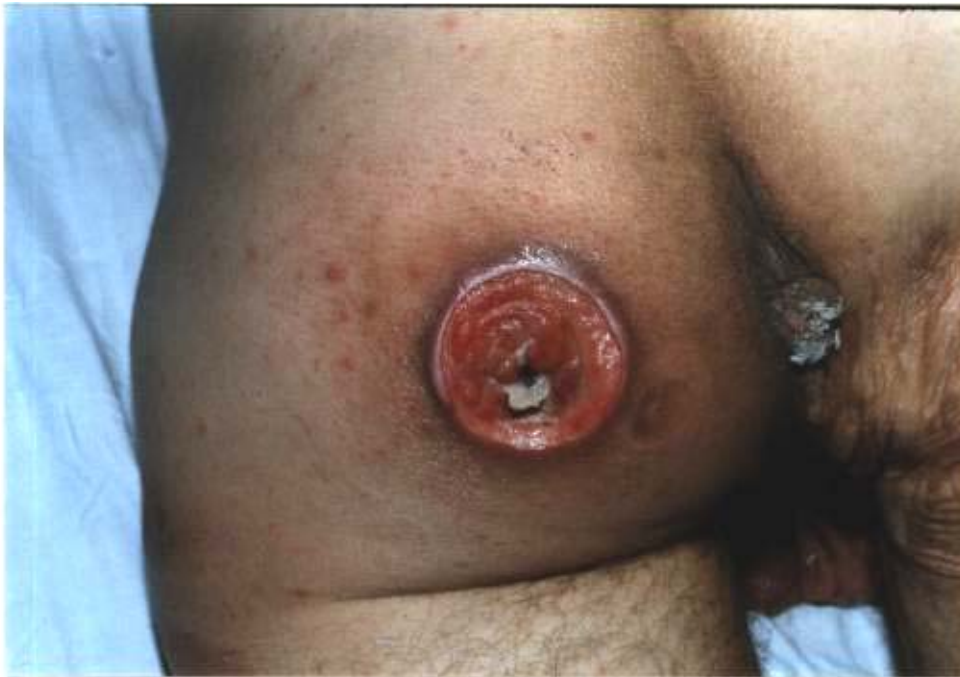- CASE 10. B.G. 51 YEAR MALE
- PARAPLEGIC PATIENT WITH EXTENSIVE SACRAL PRESSURE SORE
- 5 PHOTOS

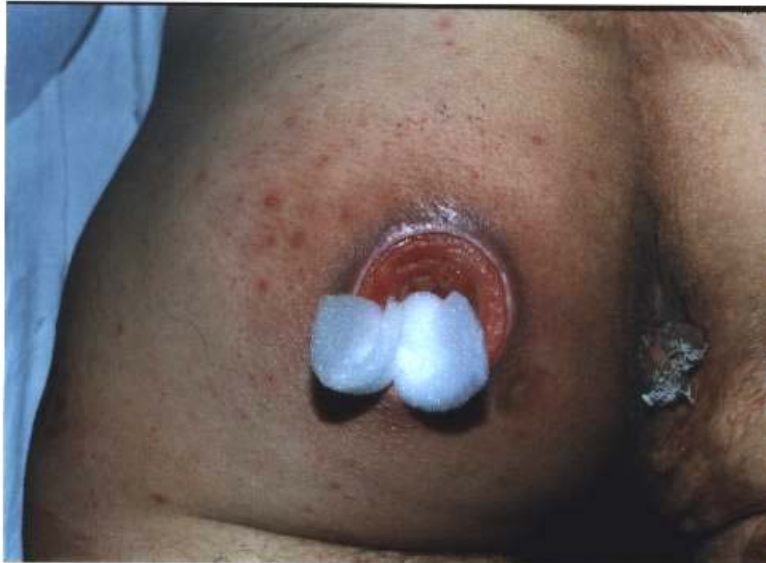
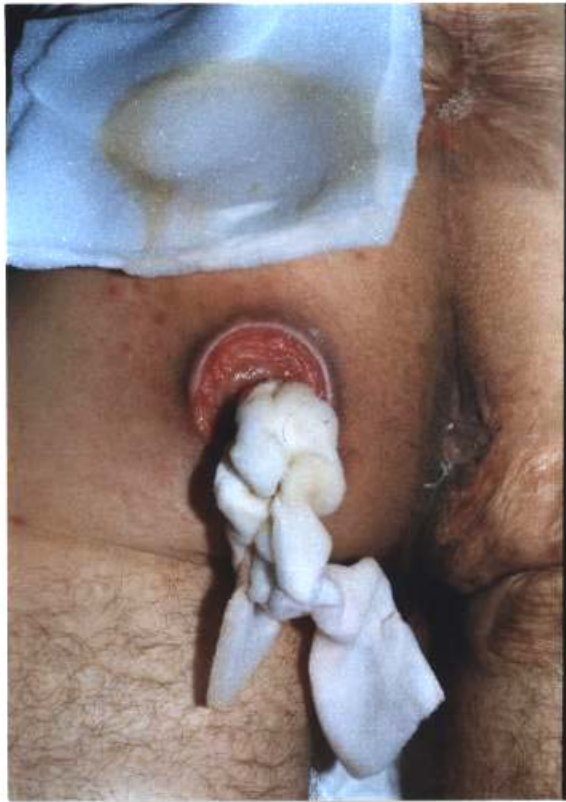


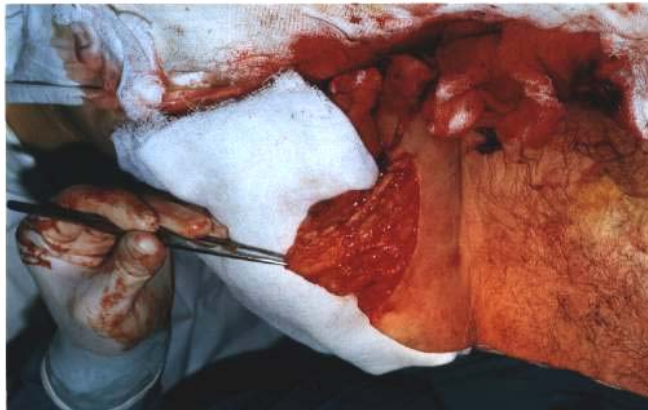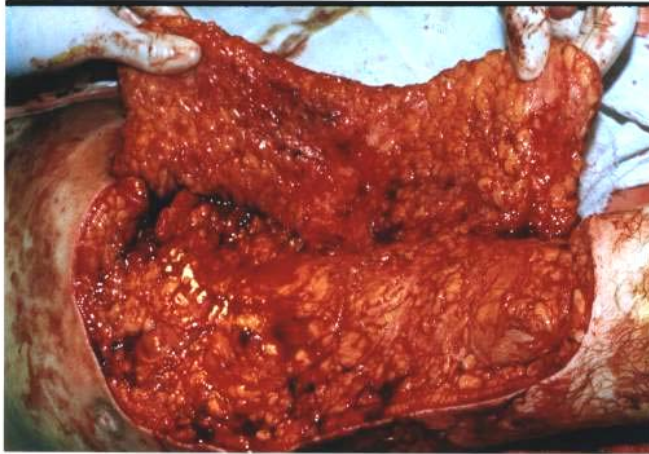
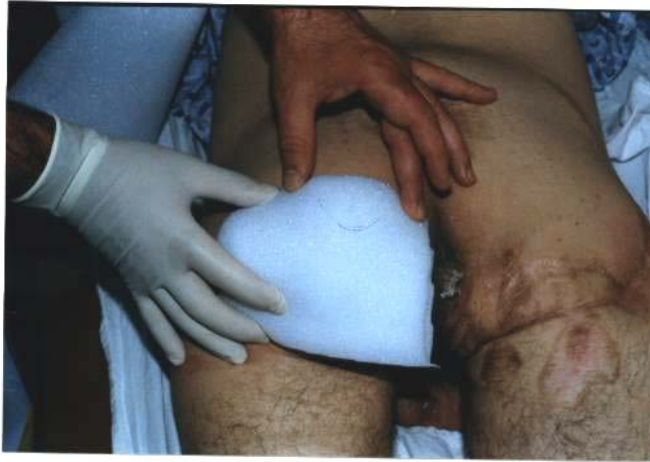- CASE 11. S.G. 30 YEAR MALE
- PARAPLEGIC YOUNG MALE WITH ISCHIAL PRESSURE SORE
- 24 PHOTOS

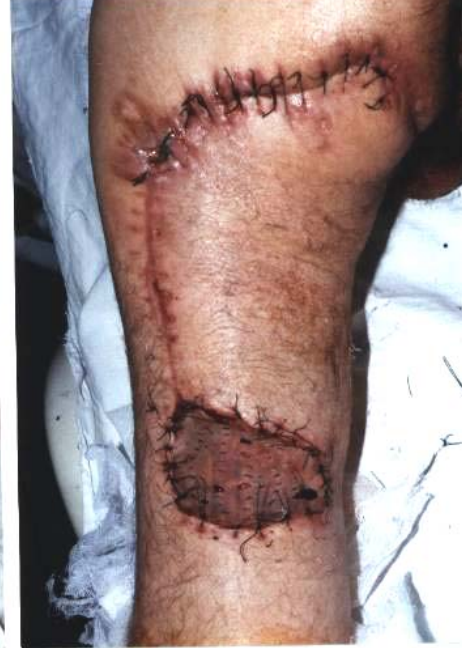
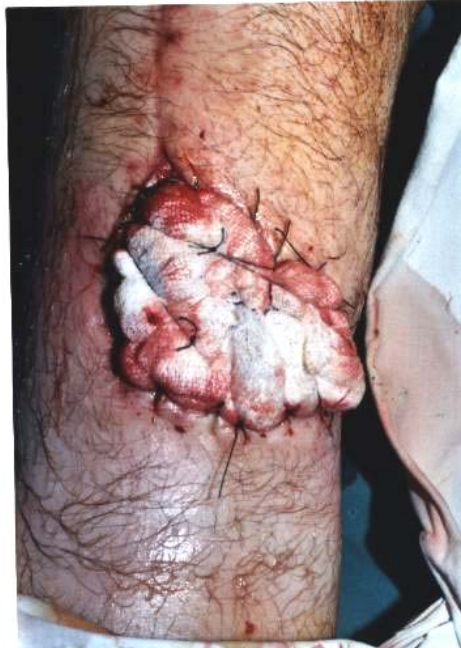
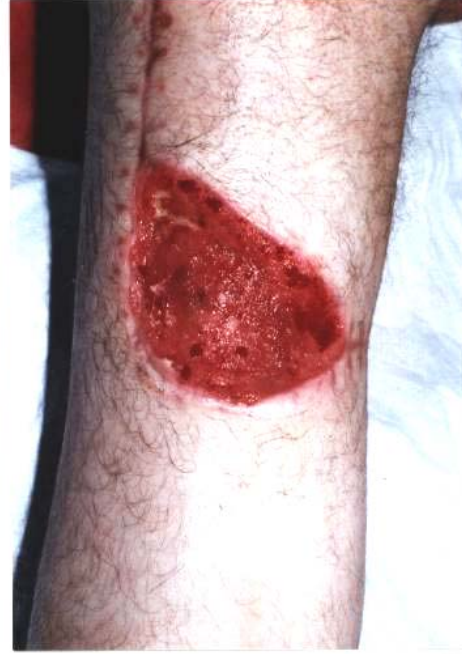
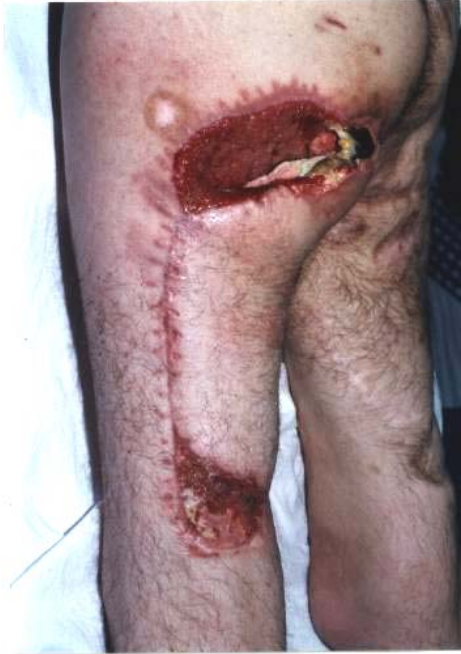


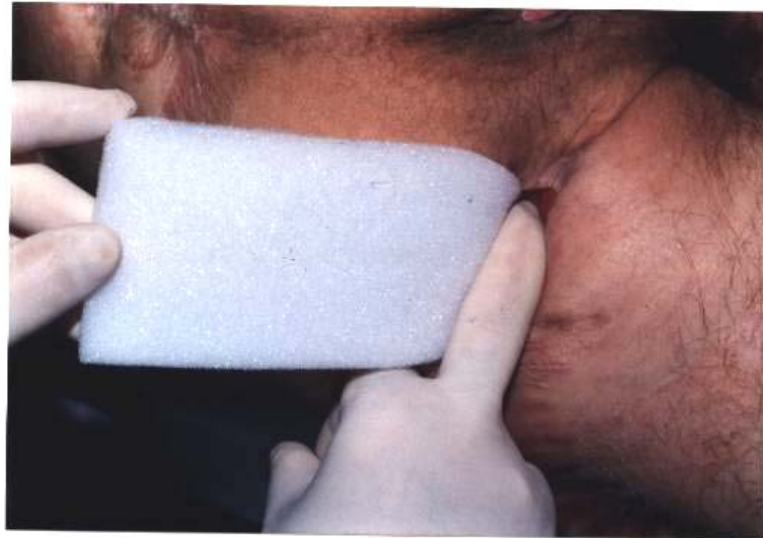
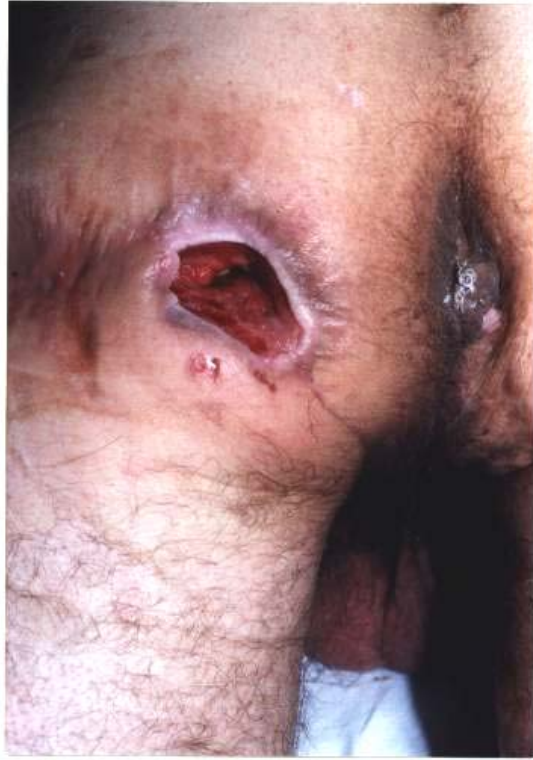
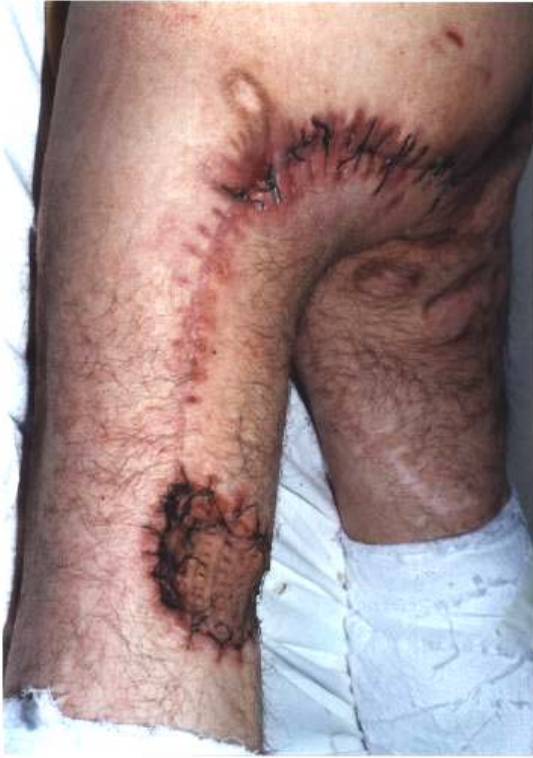


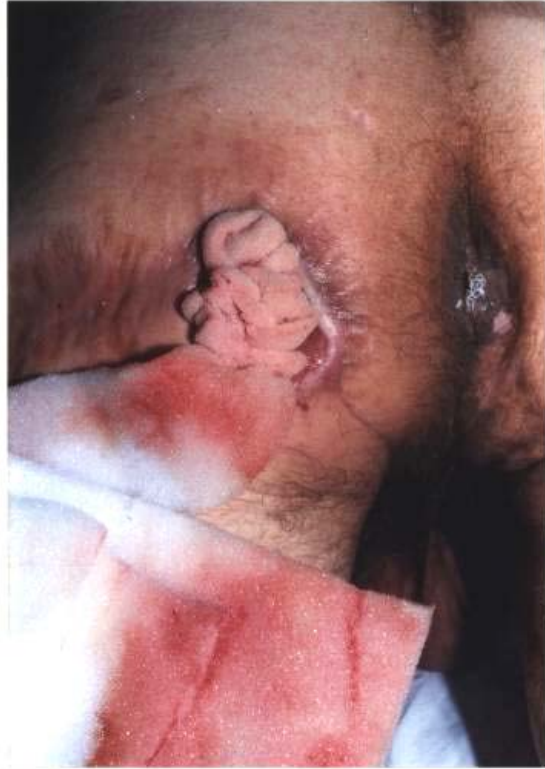
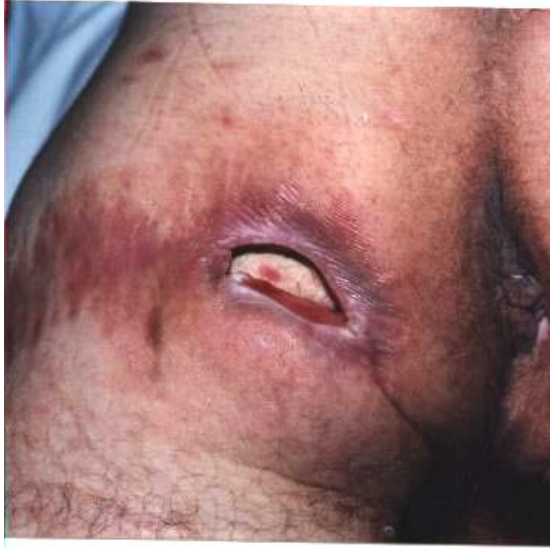


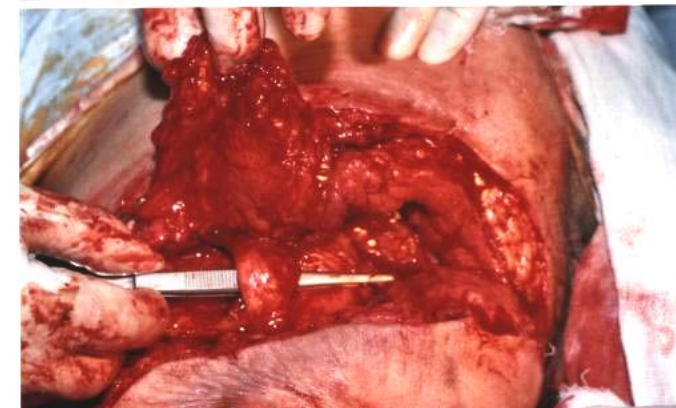
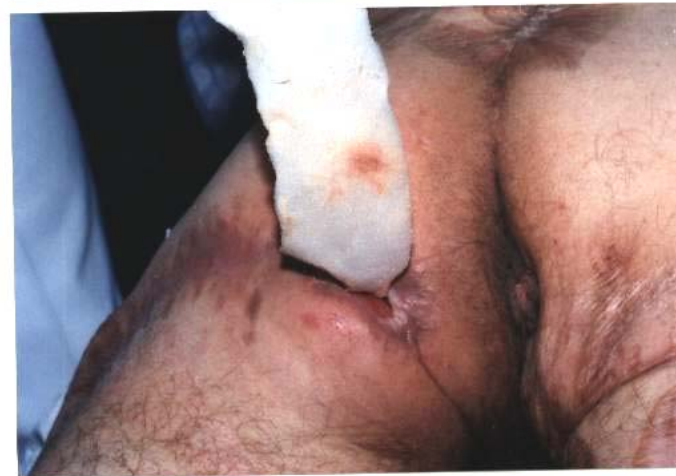
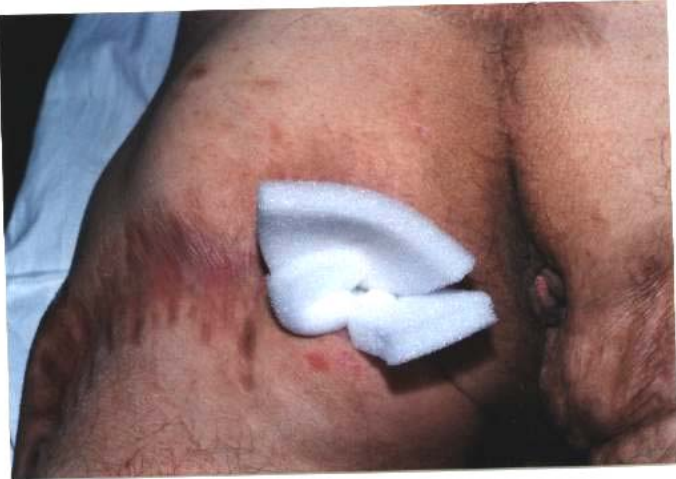


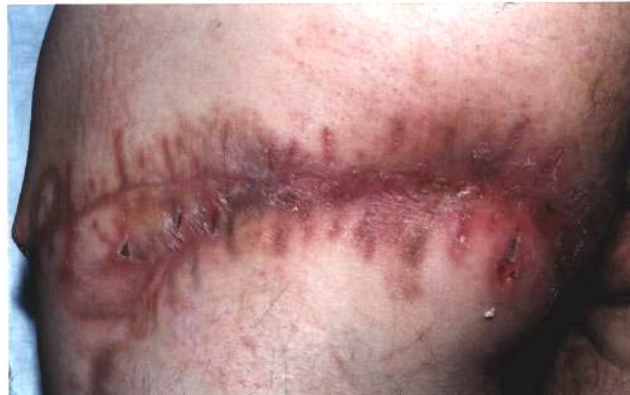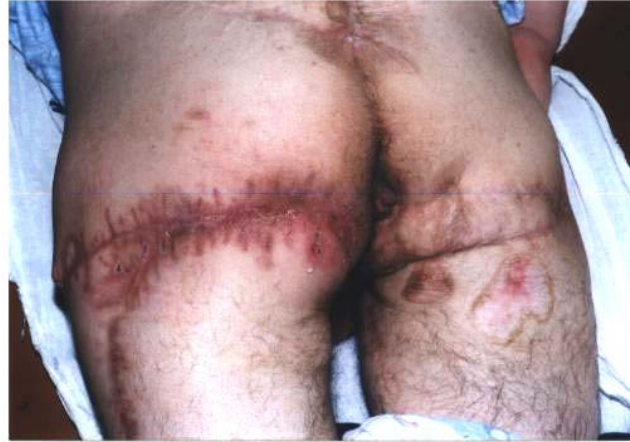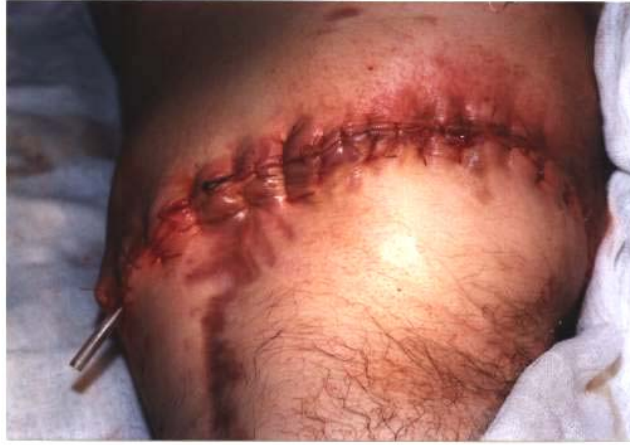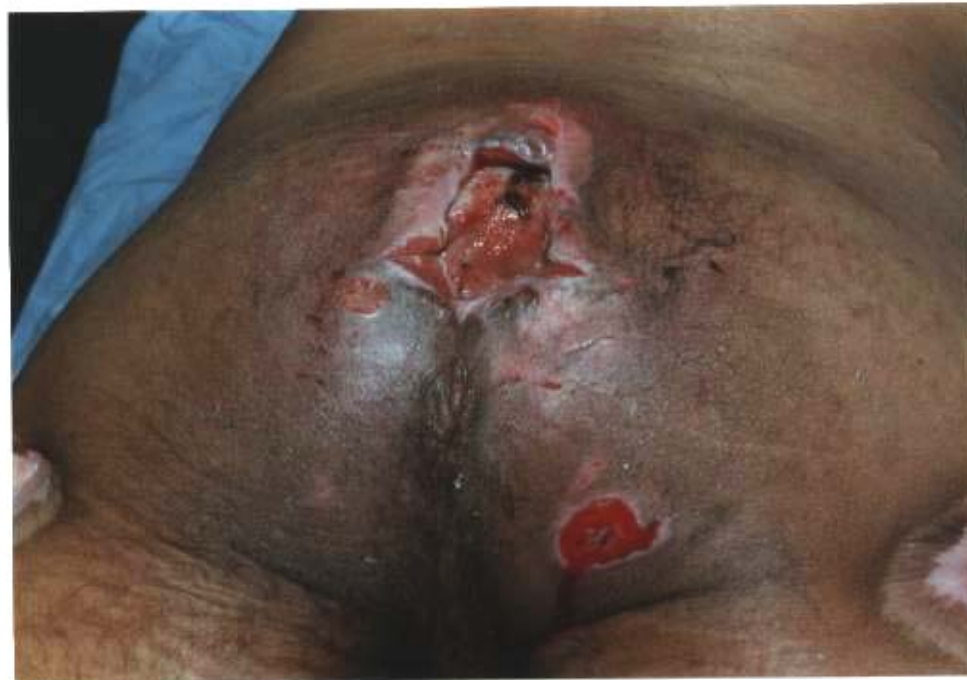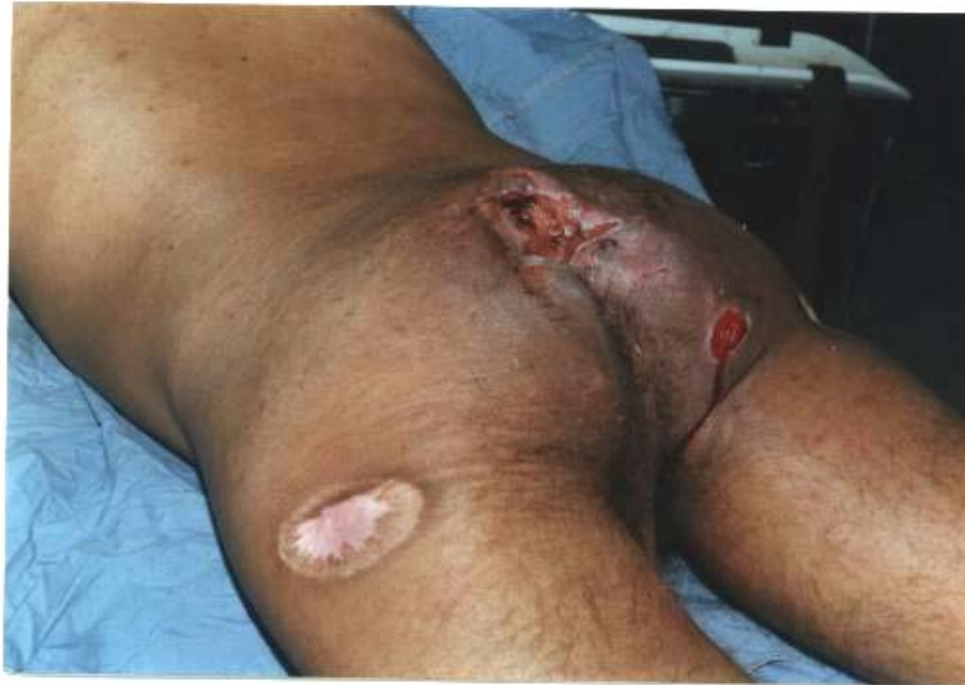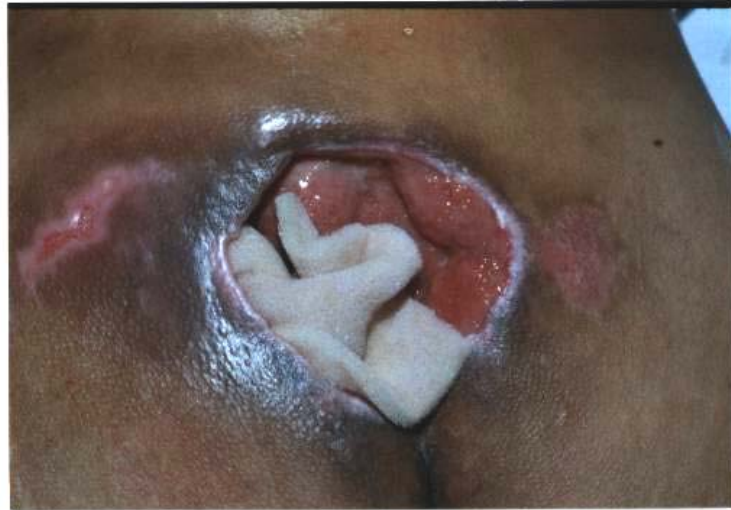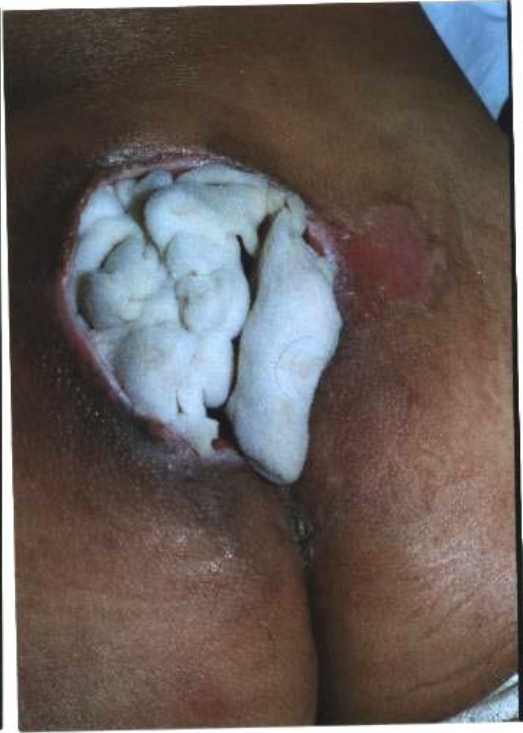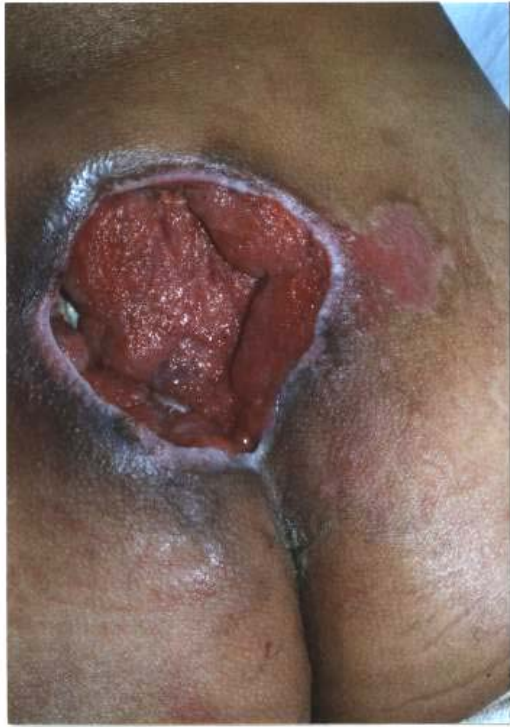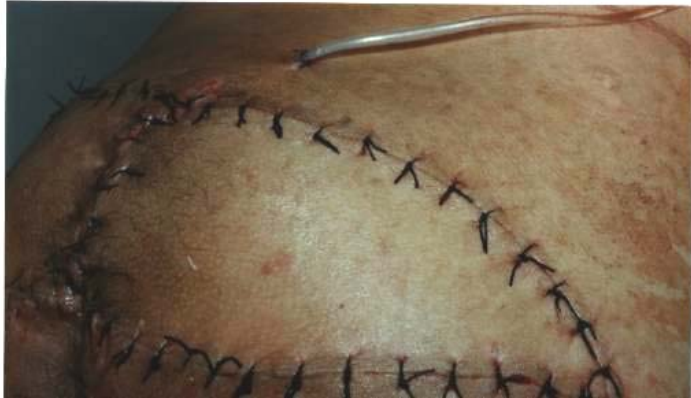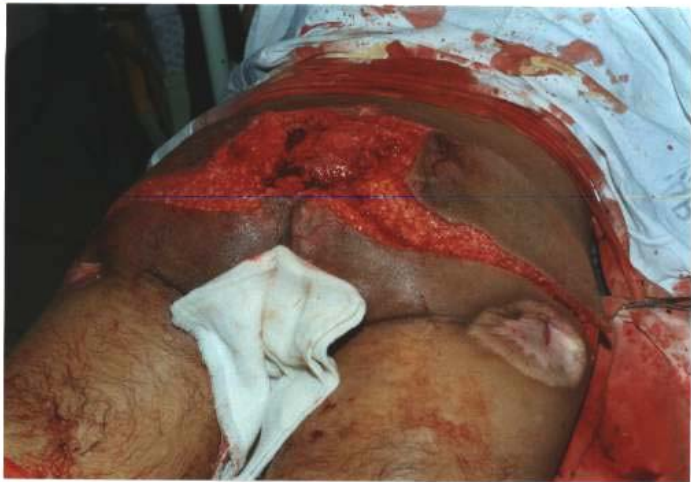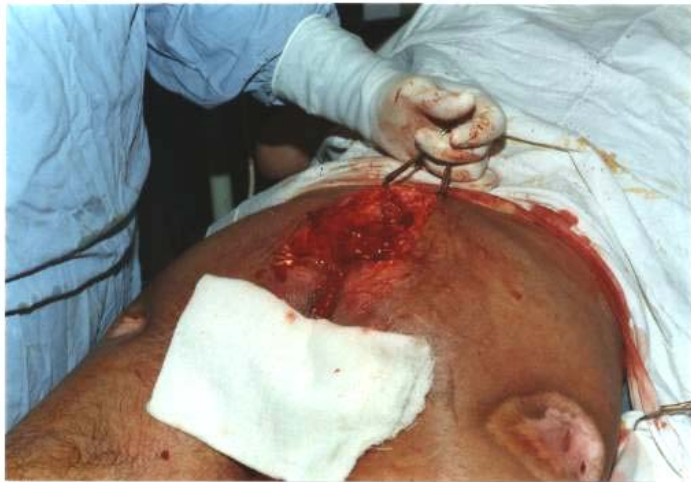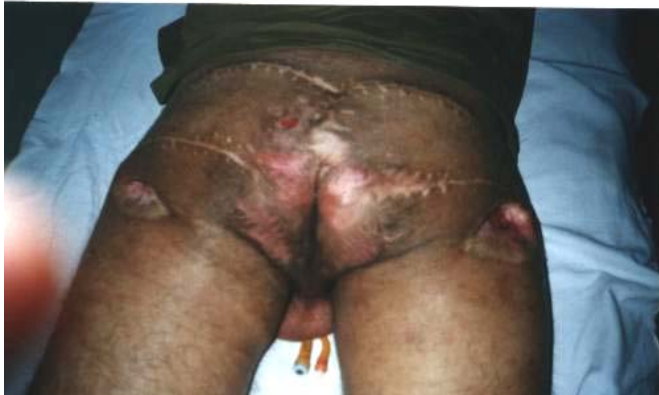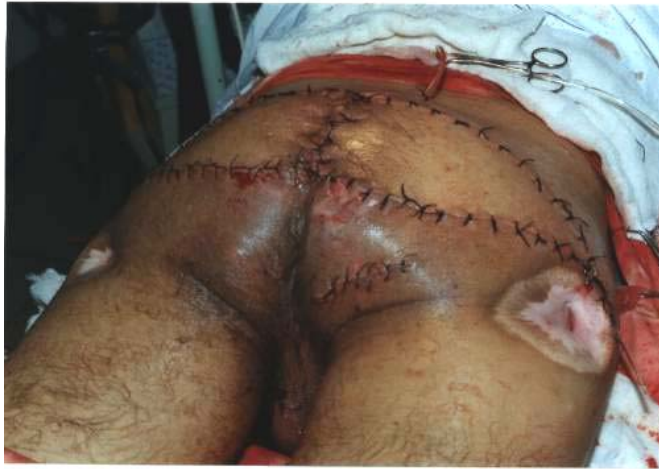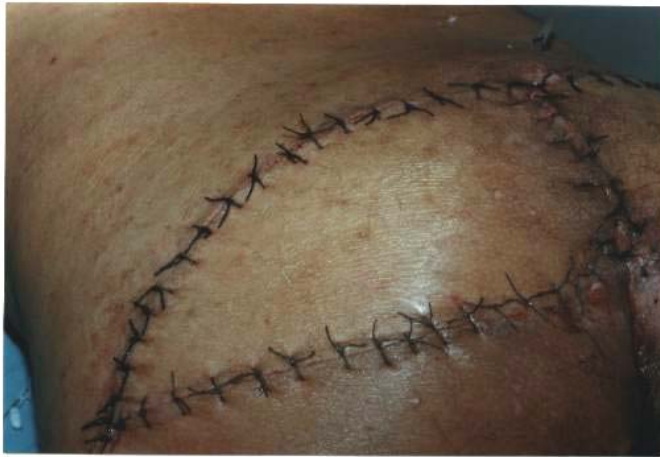- CASE 12. B.F. 26 YEAR MALE
- PARAPLEGIC YOUNG MAN WITH SUCCESSIVE SACRAL AND ISCHIAL PRESSURE SORES
- 18 PHOTOS

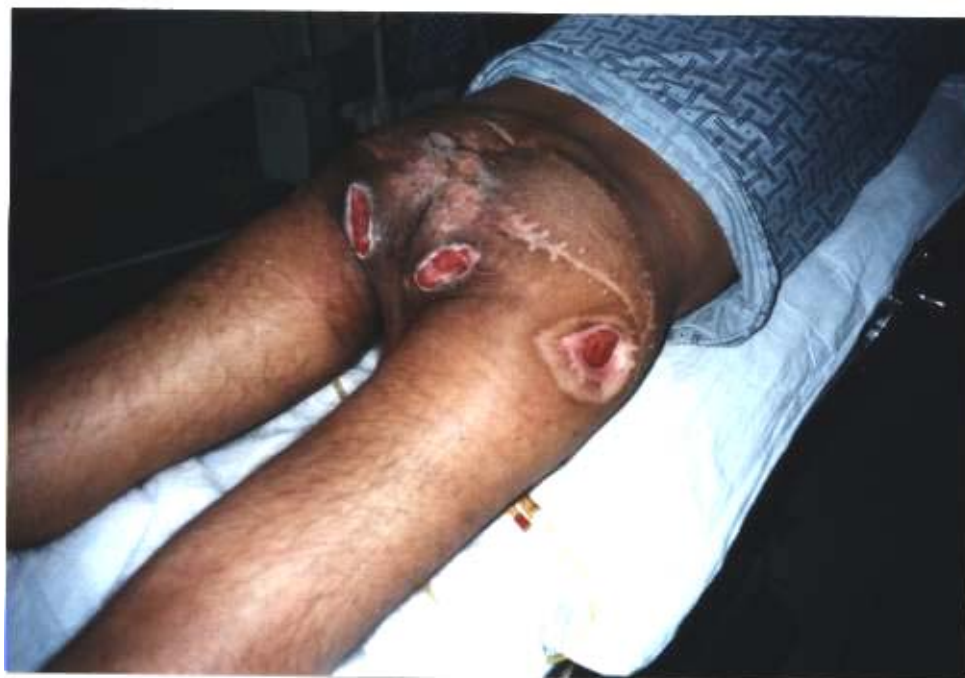
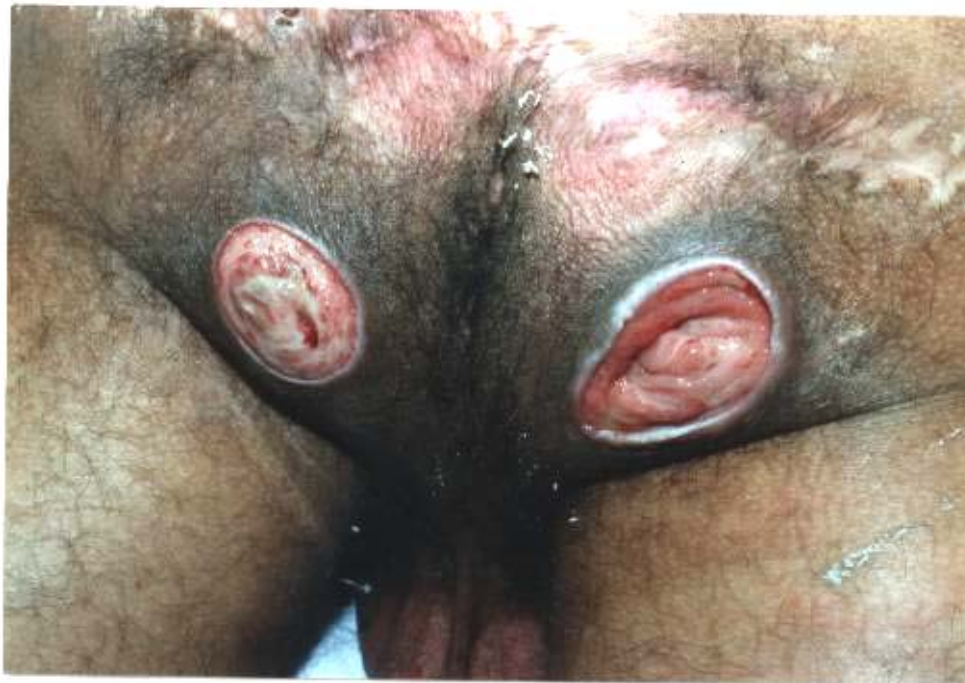


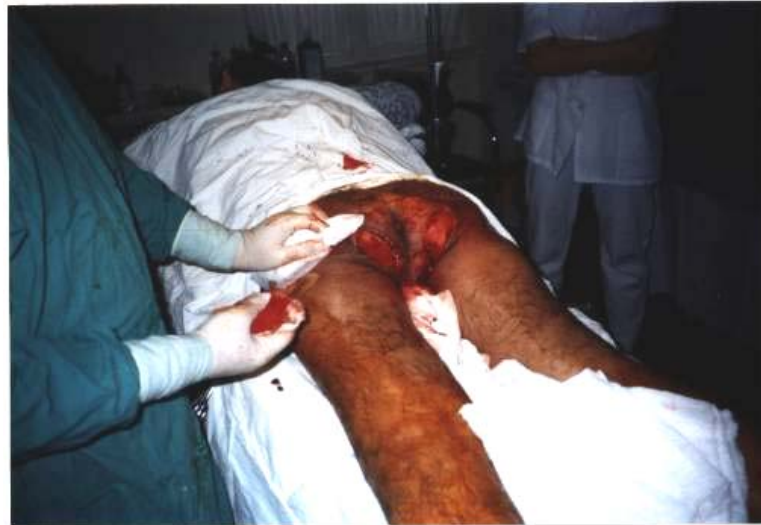
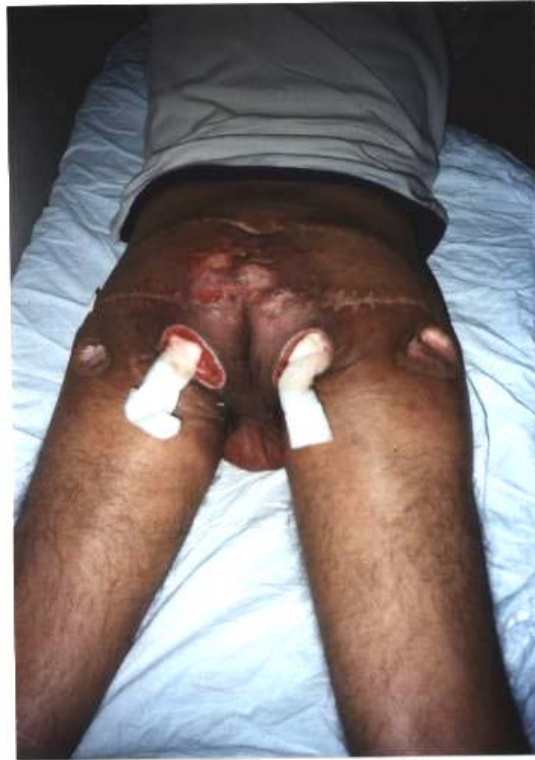


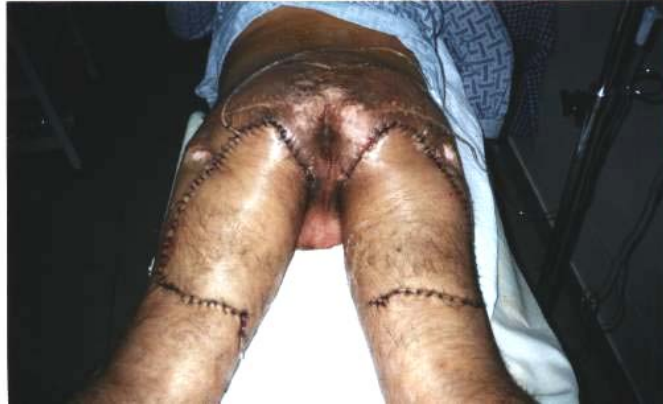
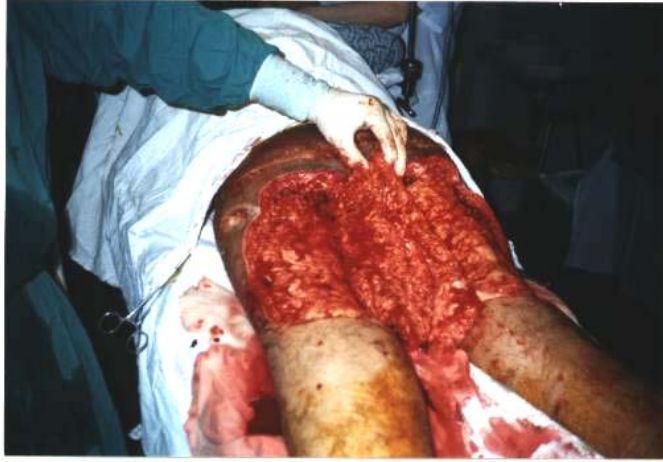
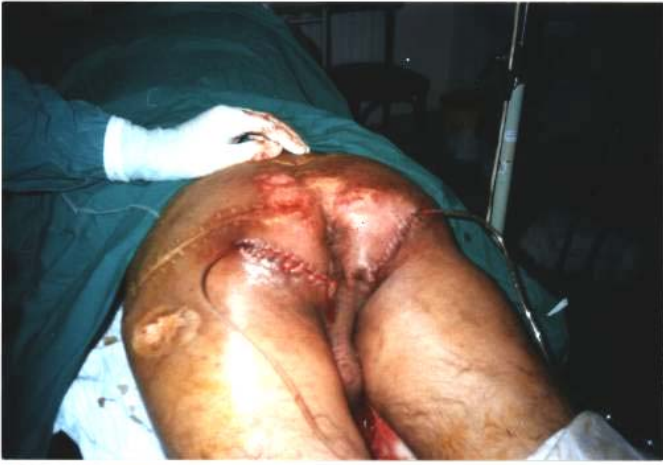




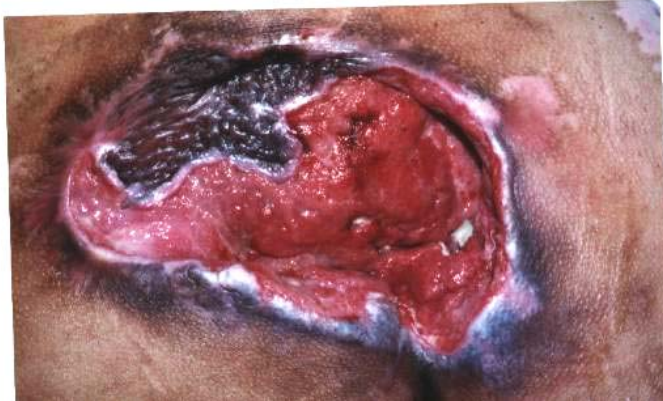
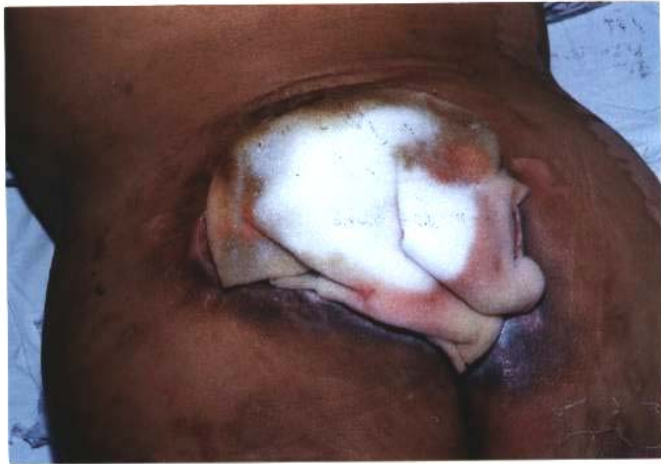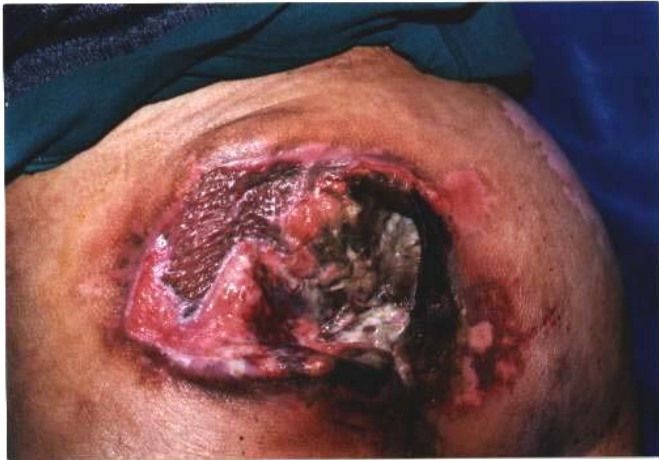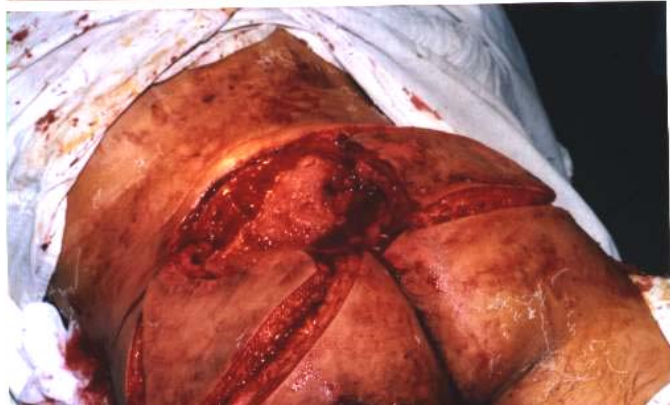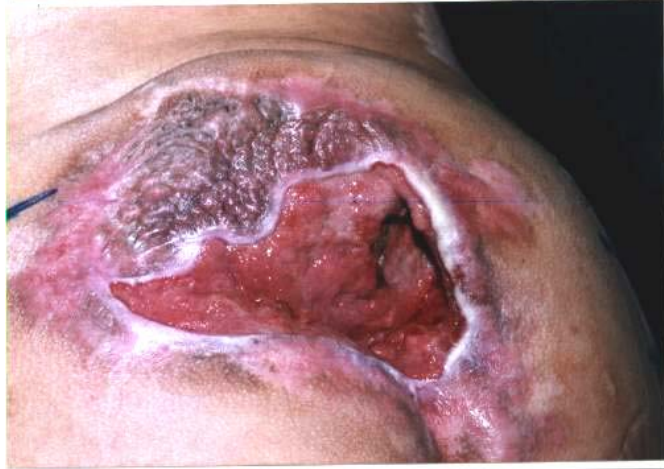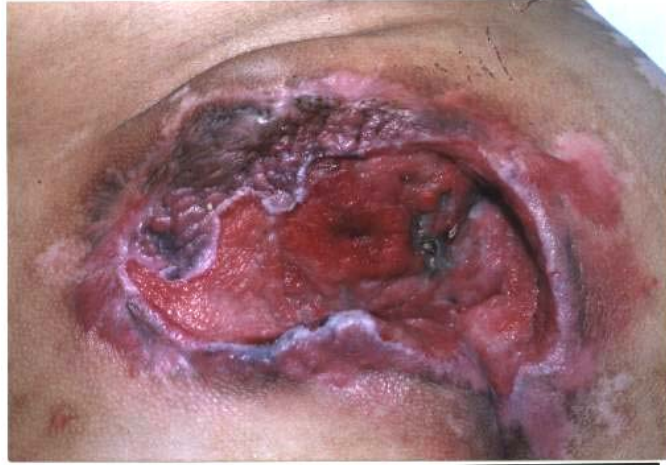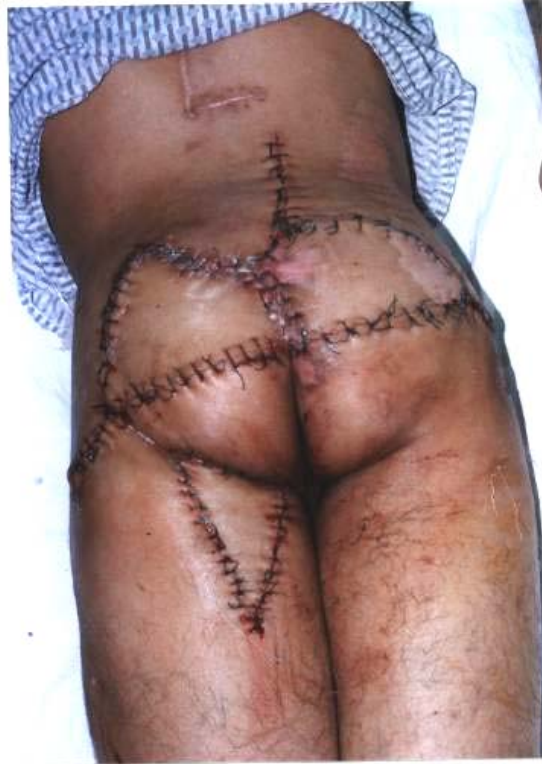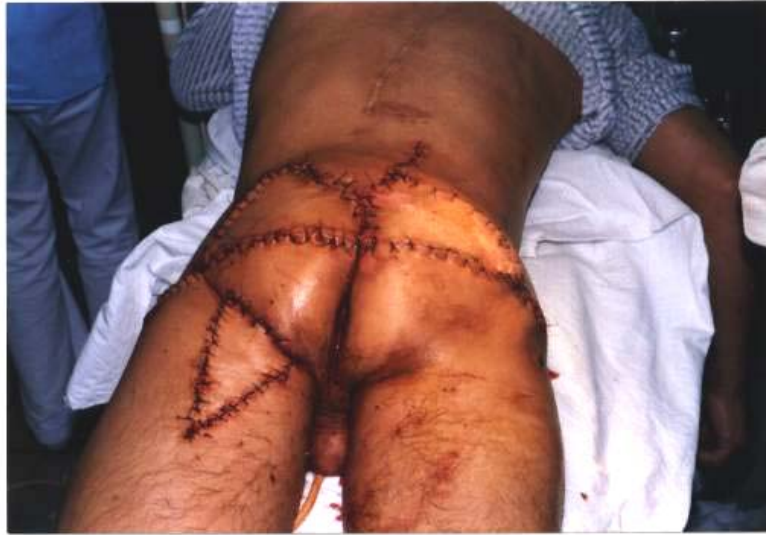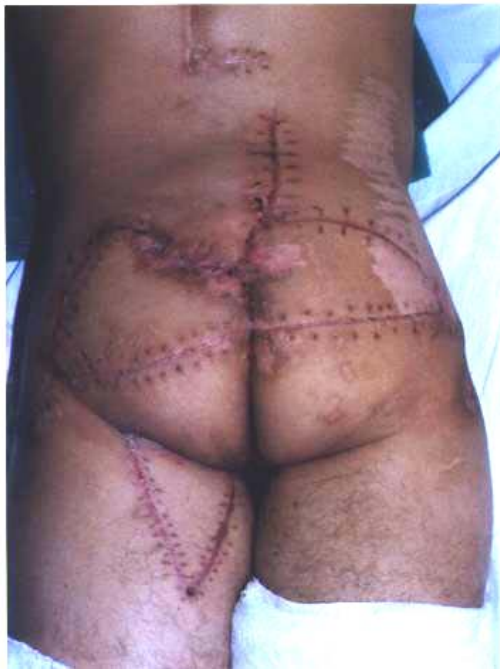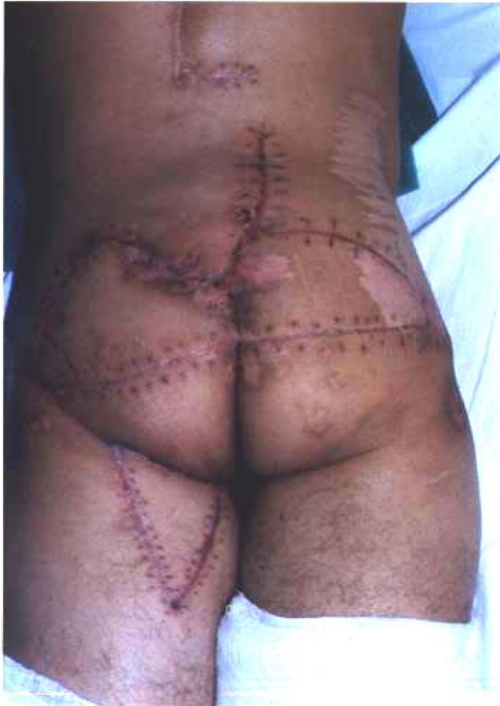- CASE 13.I.S. 39 YEAR MALE
- GIANT PARAPLEGIC PRESSURE SORE
- 10 PHOTOS



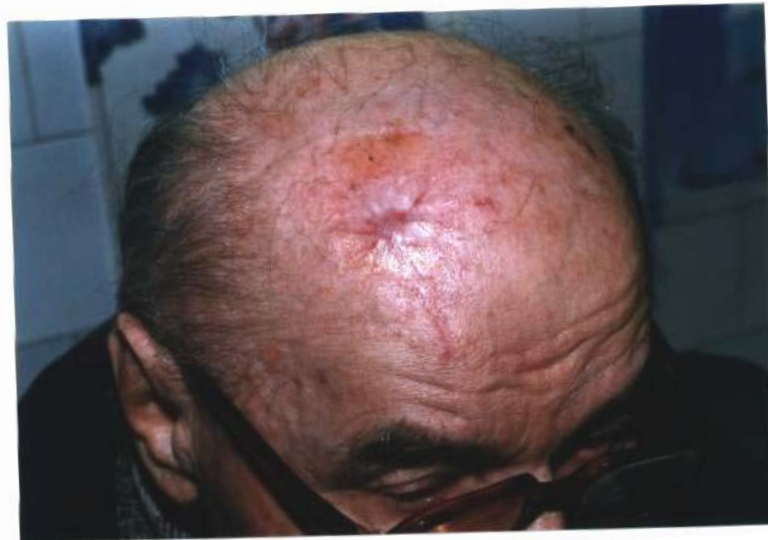
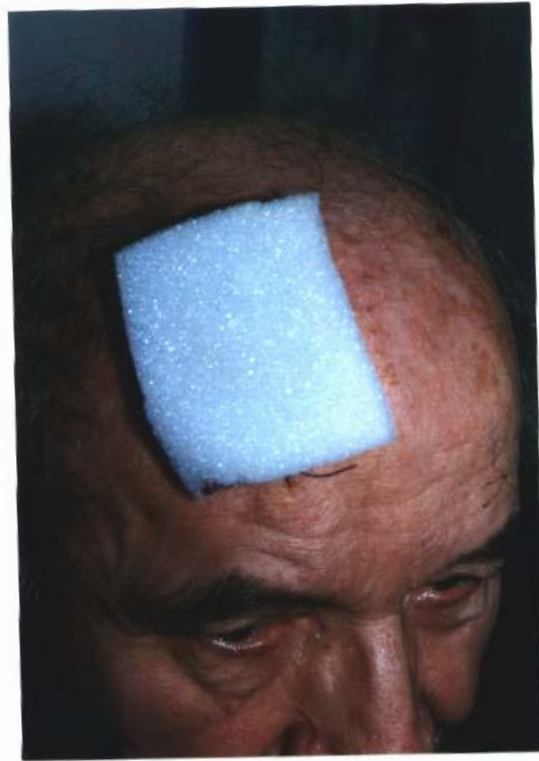
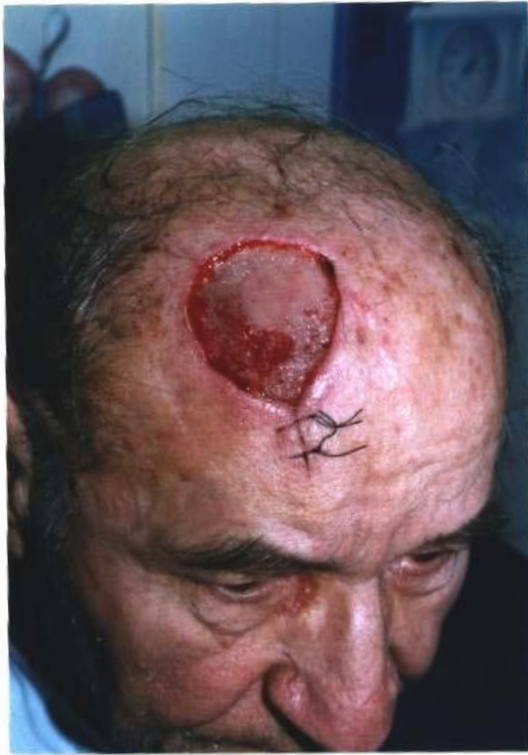


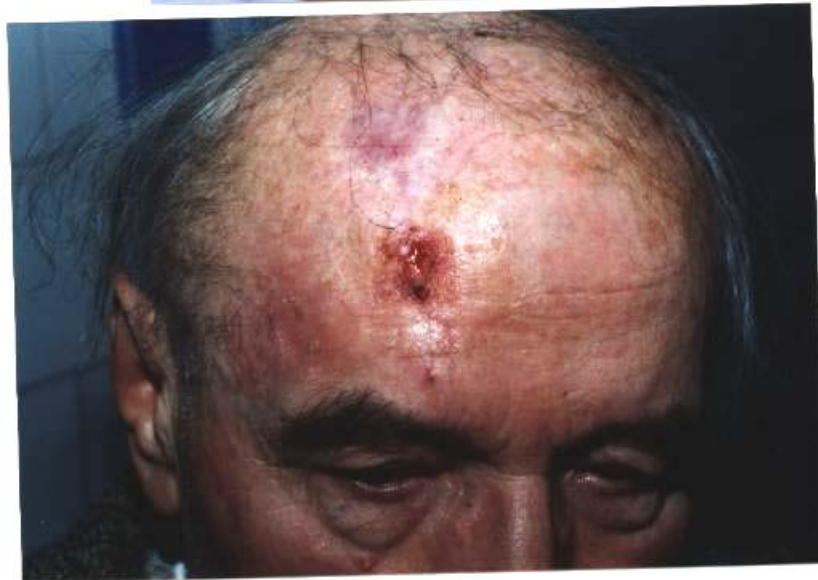
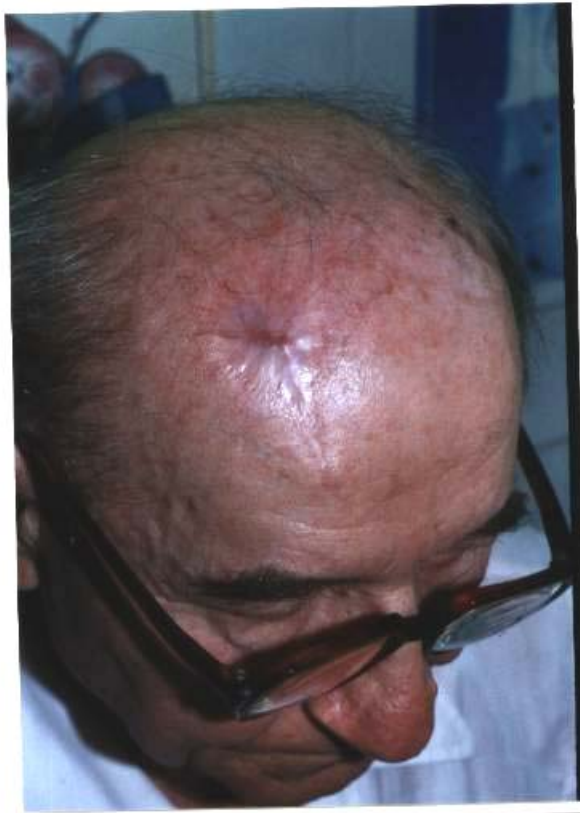

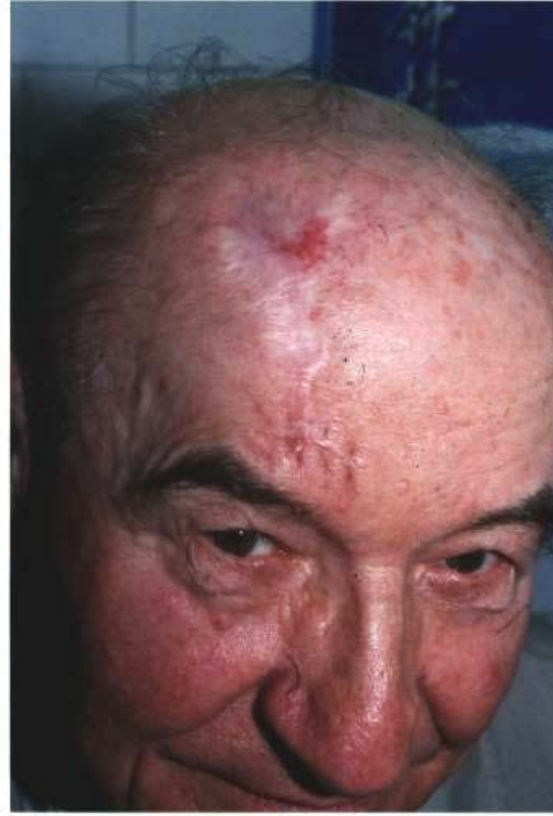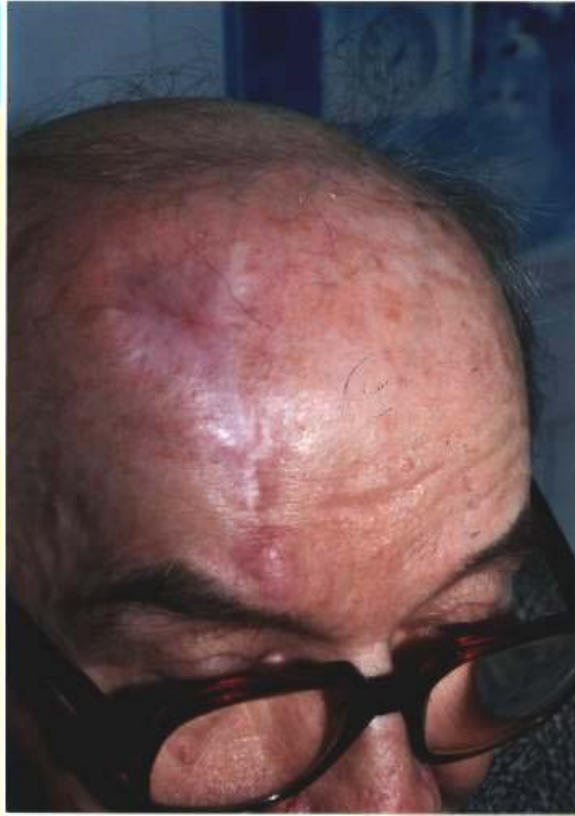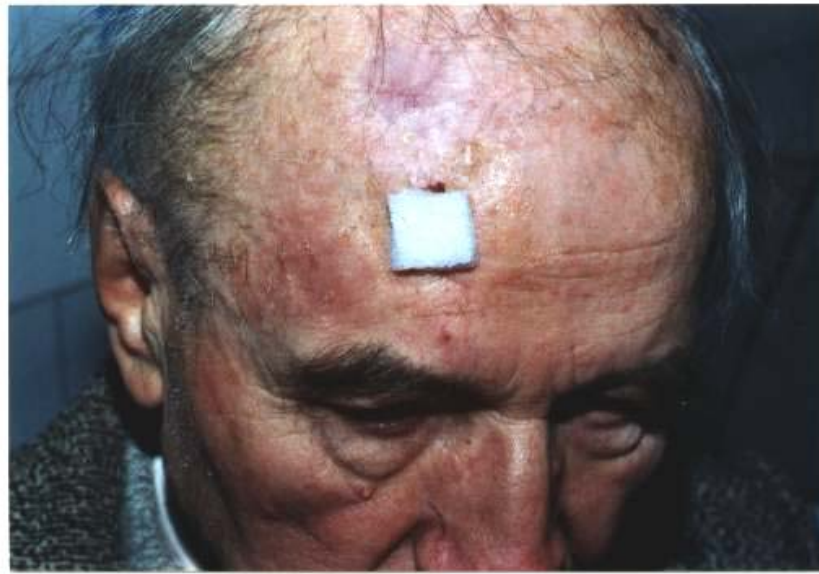- CASE 14. G.A. 80 YEAR MALE
- BASAL CELL CARCINOMA EXCISED  
ENTREATED BY „SECONDARY  
INTENTION” WITH LIGASANO
- 8 PHOTOS

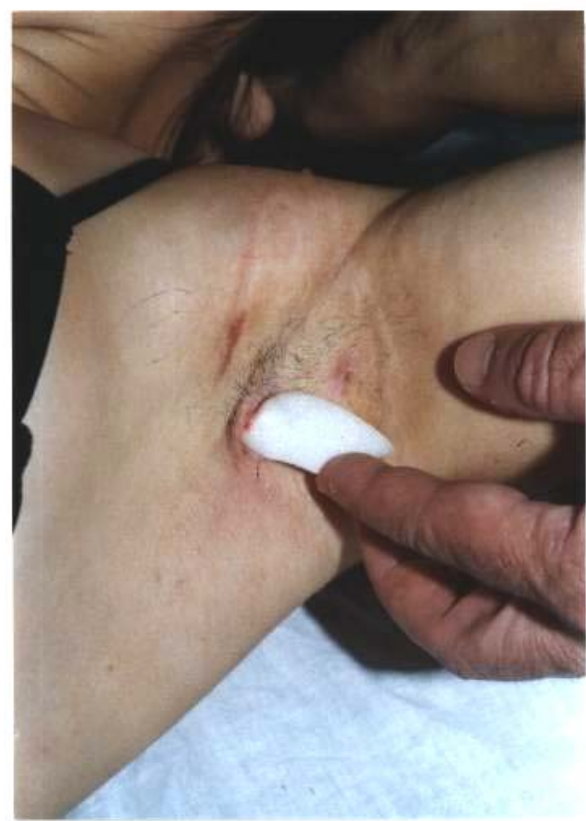
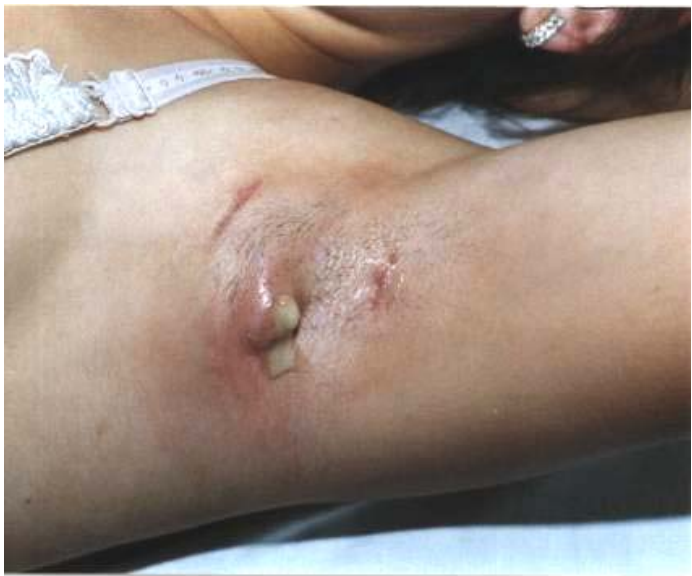


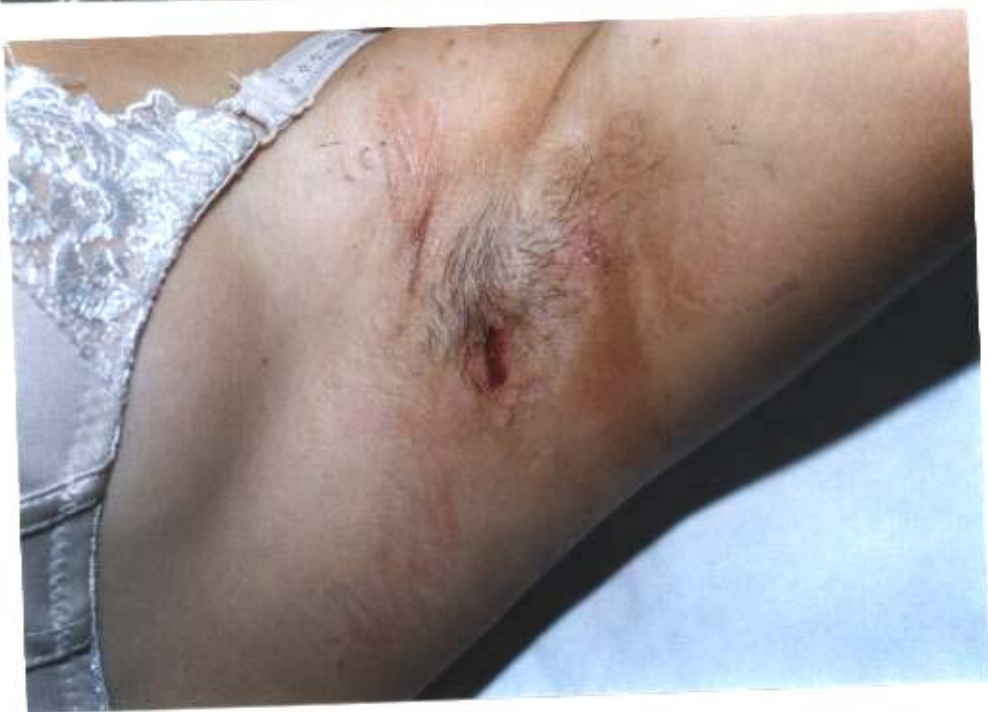
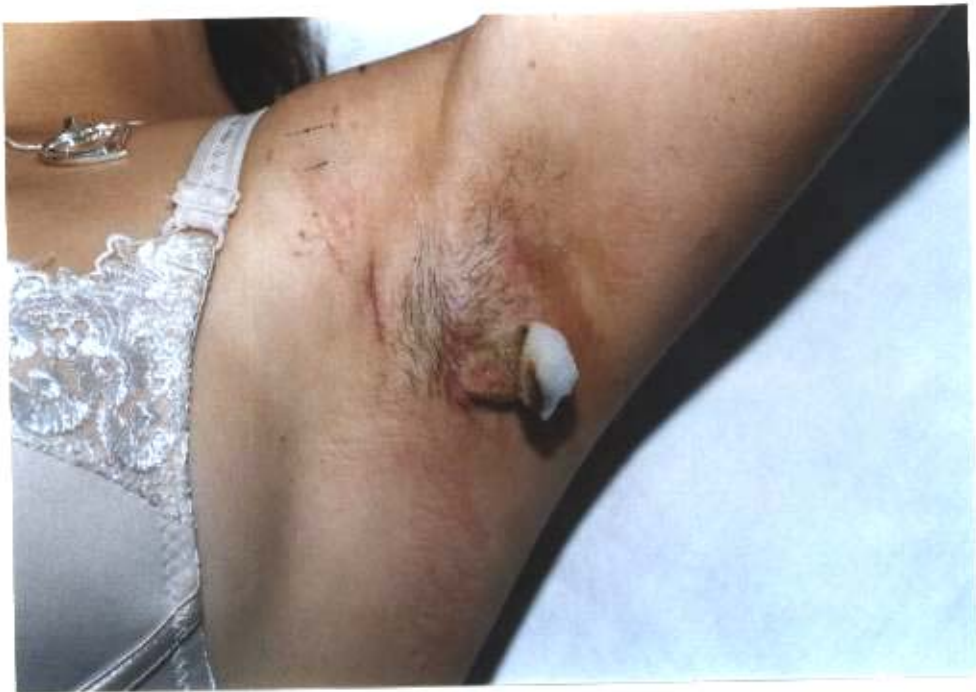
- CASE 15. S.K. 22 YEAR FEMALE
- HIDRADENITIS SUPPURATIVA OF THE LEFT AXILLA TREATED WITH LIGASANO
- 4 PHOTOS







- ALL THESE CASES LISTED ABOVE HAVE BEEN TREATED BY DR. ADRIAN BOTAN , IN THE BURN CENTRE AND PLASTIC SURGERY DEPARTMENT , EMERGENCY HOSPITAL OF MURES COUNTY ROMANIA .
- TARGU - MURES AUGUST 16 , 2004